

Rehabilitation of Edentulous Atrophic Anterior Mandible – The Role of Vertical Alveolar Distraction Osteogenesis

MATHEW O MAMPILLY¹, LATHA P RAO², JOYCE SEQUIERA³, B H SRIPATHI RAO⁴, JAGADISH CHANDRA⁵, GUNACHANDRA RAI⁶

ABSTRACT

The rehabilitation of patients with edentulous alveolar ridge is always a challenge, more so in case of a long standing atrophic mandible. Mandible, the largest movable bone in the maxillofacial skeleton is associated with many soft tissue attachments which imparts dislodging forces to prosthesis. In addition to this, the rate of resorption of the mandibular ridge is four times that of the maxilla. These factors make the environment of the mandibular arch less favorable to complete denture stability and retention. An ideal solution would be to augment the atrophic alveolar ridge with native bone of the individual which shall eliminate the possible complications, associated with conventional ridge augmentation procedures. With advent of modern technology, and increased biological understanding, the principles of distraction osteogenesis are increasingly being applied to the craniofacial skeleton and have been found to be a viable option in augmenting the native alveolar bone in the mandible. Here the application of an indigenous stainless steel vertical alveolar distraction device to augment atrophic anterior mandibular ridge is assessed in six patients.

Keywords: Alveolar distraction osteogenesis, Atrophic ridges, Edentulous mandible

INTRODUCTION

The acquisition of a third set of teeth is a long time desire of the human race. The history of this desire is perhaps as old as edentulism. The loss of teeth sets the stage for resorption of the alveolar ridges and the rate of resorption can range anywhere between 25% and 40% over a period of 1 to 2 y [1]. The edentulism compounded by the atrophic ridges poses a rehabilitation challenge in terms of stable dentures, especially in mandible, where the alveolar bone resorption is four time more than that in maxilla [1]. To overcome this problem, various soft as well as hard tissue procedures [2-5], have been tried with varied success. None of these procedures give 100% predictability and stability. Moreover these procedures have the disadvantages viz. donor site morbidity, increased chance of infection, nerve paresthesia, inability to wear denture till 3-5 months after surgery, resorption of grafted bone and soft tissue dehiscence resulting in loss of vestibular depth etc. So the search for newer methods to manage atrophic mandibular ridges is on. An ideal solution would be to augment the atrophic alveolar ridge with native bone of the individual which shall eliminate the possible complications, associated with conventional ridge augmentation procedures.

Distraction osteogenesis, a surgical technique which utilizes the body's own reparative mechanisms for hard and soft tissue reconstruction, has evolved as a useful and acceptable alternative to conventional bone grafting techniques in atrophic alveolar ridges. The first description of distraction osteogenesis of alveolar ridge in human being was given by Chin and Toth in 1996 [6]. The process of alveolar distraction osteogenesis involves mobilization and transport of a healthy segment of the basal bone to the deficient alveolar site, with native bone formation in between. Here, the application of an indigenous stainless steel vertical alveolar distraction device to augment atrophic anterior mandibular ridge is assessed in six patients.

MATERIALS AND METHODS

Distractor assembly

The indigenously developed stainless steel intraoral vertical distractor assembly has a top & bottom wings which are attached to either side of the osteotomy cuts with 1.5mm SS screws and a

stem assembly. The top wing has four holes in the X-Y plane & an O- slot, whereas the bottom wing has a D slot which provides the stem assembly with anti rotation locking. The stem assembly has a crown & root part [Table/Fig-1]. The crown part provides with a square projection which fits to the activator. The fine threaded screw at the bottom part of the crown fits into the internal threading on the top position of the root. The pitch of the screw is 0.4mm and the distraction height can be upto 9mm.

Patient selection

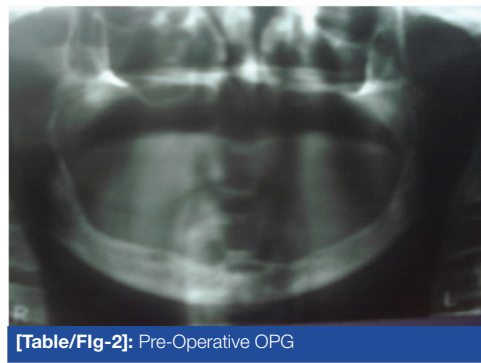
Six patients in the 40-60 y of age group were included in the study. The study was conducted at Yenepoya dental college Mangalore, India for a period of three years. Inclusion criteria for the study were those patients with edentulous atrophic mandibular ridges, which were considered insufficient for a successful rehabilitation with complete dentures. The deficiency of the vertical alveolar height was 5-8mm. The height of the basal bone at atrophied site should be minimum of 15mm. All patients were explained the procedure and consent was obtained. The exclusion criteria were those patients with any form of local or systemic pathologies. Patient with systemic disorders which could not be controlled or which causes significant surgical risks was also excluded from the study. The ridge height was measured by tracing the Orthopantomograph (OPG), from the crest of alveolar ridge to the lower border of mandible [Table/ Fig-2].

Surgical technique

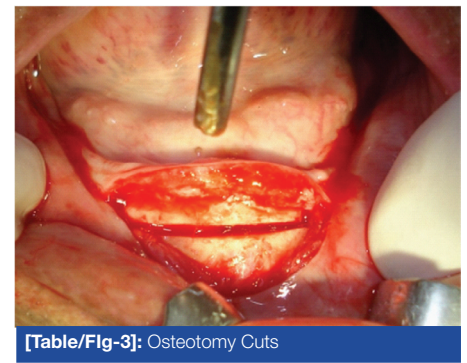
The horizontal incision was placed slightly buccal to the alveolar ridge from 1st premolar to opposite side 1st premolar edentulous region with vertical releasing incisions on either side ensuring that the lingual periosteal attachment was intact to preserve vascularity of osteotomised segment. The distractor assembly was oriented parallel to lower border of mandible & position marked. 'U' shaped osteotomy with superiorly diverging vertical cuts was performed using the piezoelectric surgical unit. The distractor assembly was fixed in the predetermined position after confirming the completeness of the osteotomy. The flap was closed over the distractor with just the crown part of the stem assembly exposed in the oral cavity. OPG was taken after the surgical procedure to determine whether the vector of the distractor device was kept as planned [Table/Fig-3-5].



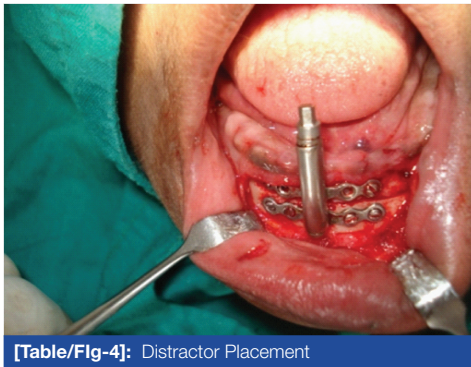
[Table/Fig-1]: Alveolar Distractor



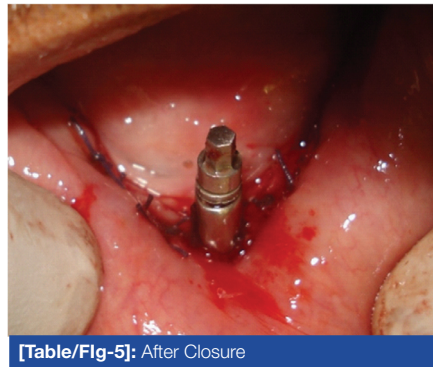
[Table/Fig-2]: Pre-Operative OPG



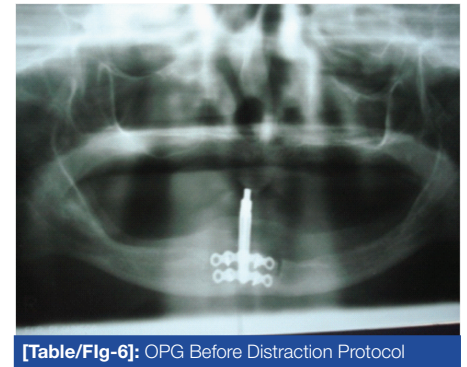
[Table/Fig-3]: Osteotomy Cuts



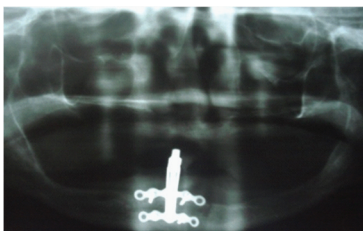
[Table/Fig-4]: Distractor Placement



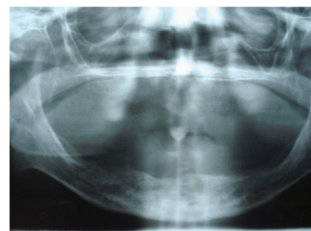
[Table/Fig-5]: After Closure



[Table/Fig-6]: OPG Before Distraction Protocol



[Table/Fig-7]: OPG After Distraction Protocol



[Table/Fig-8]: OPG Post Consolidation

S. NO	Pre-operative ridge height (mm)	Post-operative ridge height (mm)	Gain in ridge height (mm)
1	31.5	35.5	5
3	33.5	39.5	6
3	28	33	5
4	27	30	3
5	29	34	5
6	30	35	5

[Table/Fig-9]: Clinical measurements

Distraction protocol

After the latency period of five days, alveolar distraction was carried out at the rate of 1mm/day i.e., two 360° turns per day (one 360° twice daily one turn=0.5mm), the rhythm was one turn in the morning one in the evening till the desired increase in bone height was achieved. Immediately after the distraction regime was over another OPG was taken, to check the vertical augmentation of the ridge, and to check any lingual tilting of the osteotomized segment. Consolidation period was two months after which the device is removed under local anaesthesia and another OPG was obtained [Table/Fig-6-8].

RESULTS

Among the six patients distraction could not be done in one patient because of the lingual tilt of the osteotomised segment along with the distractor. In rest of cases ridge height was measured clinically as well as radiologically, after the removal of distraction device and

S. NO	Pre-operative ridge height (mm)	Post-operative ridge height (mm)	Gain in ridge height (mm)
1	31.5	35.2	4.8
3	33.5	38.2	4.7
3	27	32	5
4	26	29	3
5	27	32	5
6	29	34	5

[Table/Fig-10]: Radiographic measurements

was compared with preoperative ridge height. The vertical elevation of the transport segment was between 4-6 mm [Table/Fig-9, 10]. All the patients were followed up for a period of six months. Most of the patients have undergone complete denture prosthetic rehabilitation, follow up of six cases for a period of six months shows that most of the ridges have undergone resorption of at least 0.5-1mm.

DISCUSSION

The alveolar bone is often referred to as a 'selfish bone' due to its propensity to undergo resorption once the tooth it encases gets exfoliated or is extracted. The natural teeth transmit occlusal load to the alveolar bone through their periodontal ligament in the form of a tensile strain that acts as a stimulating factor for maintenance of its architecture and contour. After the loss of tooth, as the alveolar bone is no longer subjected to tensile strain, it undergoes atrophy. The rate of resorption can be as severe as 0.4mm per year in the mandible as compared to 0.1 mm per year in the maxilla [7], thus necessitating prompt augmentation of the residual ridge especially in the mandible.

Because the defect involves both hard and soft tissues in a wet and mobile environment, the alveolar ridge is one of the most difficult areas of the human body to reconstruct. Different authors have suggested various treatment modalities, which can range from deepening the vestibule by vestibuloplasty [2] or augmentation of the alveolar bone by interpositional grafts [4] or visor osteotomy [5]. These conventional techniques were found to be unpredictable and short lasting in achieving / maintaining the desired augmentation.

Distraction osteogenesis is a technique that has gained immense popularity in recent years. Based on the tension-stress principle as described by Ilizarov [8] the technique was originally recommended for treatment of congenital maxillofacial deformities like hemifacial microsomia [9]. Due to its versatility, relative simplicity, and the ability to be performed in an office setting, it is now being widely used for many other indications including augmentation of the atrophic alveolar ridge [10]. In alveolar DO, in line with the basic principles of tissue engineering, gradual traction of the pedicled bone fragment is followed by simultaneous osteogenesis (bone) and histiogenesis (functional soft tissue matrix) [11, 12]. Other advantages of distraction osteogenesis over bone grafting include lack of bone graft donor site morbidity.

The main types of alveolar distractor available are, Endosseous type like LEAD (Leibinger Endosseous Alveolar Distraction) System, Extraosseous type like TRACK (Tissue Regeneration by Alveolar callus distraction Koeln) 1.0 and TRACK 2.3 and Implant distractor (DIS-SIS distraction implant SIS Inc) [13].

In our clinical scenario, these distractors would have been financially nonviable. Hence, we used an indigenously developed stainless steel alveolar distractor developed by Sirag surgicals.

Out of six cases only one had to be discontinued due to the unfavorable lingual tilting of the osteotomised segment along with the distractor, may be due to the genial muscle pull of the osteotomised segment, as the cut would have gone below the genial tubercles because of the severely atrophic ridge. In order to avoid this complication reflection of the genial muscles from the genial tubercle can be done by giving a small incision on the lingual side at the level of genial tubercle and dissecting out the muscles supra periosteally before giving osteotomy cuts. Necessary vertical augmentation could be achieved in all cases facilitating successful complete denture rehabilitation.

The amount of vertical deficiency in our study, ranged between 5-7 mm. However, other studies have successfully attempted and achieved a vertical distraction to the extent of 13 mm [14]. All the patients were followed up for six months.

The disadvantage for vertical alveolar distractions is multiple surgeries. The inconvenience of the patient of having a distractor device placed intraorally for more than three months [15].

CONCLUSION

Alveolar reconstruction is challenging because the deformity involves deficiencies in both the bone and mucosa. Alveolar distraction osteogenesis has become clinically practical because of the development of miniature internal distraction devices. Further modification of the distractor prototype used here would require further modifications as to provide greater activation span and would have to be used in a large sample size with adequate follow up.

REFERENCES

- [1] Misch Cark E. *Text book of contemporary implant dentistry*: 1993 -136.
- [2] Kazanjian VH. Surgery as an aid to more efficient service with prosthetic dentures. *J Am Dent Assoc.* 1935;22:566.
- [3] Kethley JH and Gamble J. The lipswitch: a modification of Kazanjian's labial vestibuloplasty. *J Oral Surg.* 1978;36:705.
- [4] Canzona, et al. Autogenous bone grafts in augmentation of the edentulous canine mandible. *J oral Surg.* 1976;34:879.
- [5] Harle F. Visor osteotomy to increase the absolute height of the atrophied mandible: a preliminary report. *J Maxillofacial Surg.* 1975;7:257.
- [6] Amir LR, Becking AG, Jovanovic A, Perdijk FBT, Everts Vertical distraction osteogenesis in the human mandible: a prospectivemorphometric study. *Clin Oral Impl Res.* 2006;17:417–25.
- [7] Cawood JI, et al. Reconstructive preprosthetic surgery. Anatomical considerations. *Int J Oral Maxillofac Surg.* 1991;20:75- 82.
- [8] Ilizarov GA, Ledyayev VI. The replacement of long tubular bone defects by lengthening distraction osteotomy of one of the fragments 1969. *Clin Orthop Relat Res.* 1992;7-10.
- [9] McCarthy JG, Schreiber J, Karp N, Thorne CH, Grayson BH. Lengthening the human mandible by gradual distraction. *Plast Reconstr Surg.* 1992;89(1):1-8; discussion 9-1.
- [10] Saulacic N, Iizuka T, Martin MS, Garcia AG. Alveolar distraction osteogenesis: a systematic review. *Int J Oral Maxillofac Surg.* 2008;37:1-7.
- [11] Chin M. Distraction osteogenesis for dental implants. *Atlas Oral Maxillofac Surg Clin North Am.* 1999;7:41–63.
- [12] Hidding J, Lazar F, Zoller JE. First results in vertical distraction osteogenesis of the atrophic alveolar ridge. *Mund Kiefer Gesichtschir.* 1999;3:S79–83.
- [13] Gaggl A, Schultes G, Kärcher H. Distraction implants: a new technique for alveolar ridge augmentation. *J Cranio maxillofac Surg.* 1999;27:214–21.
- [14] Schmelzeisen R, et al. Distraction osteogenesis in mandible with a motor driven plate: a preliminary animal study. *Br J Oral Maxillofac Surg.* 1996;34:375-78.
- [15] FBT Perdijk, GJ Meijer, PJ van Strijen, R Koole. Complications in alveolar distraction osteogenesis of the atrophic mandible. *Int J Oral Maxillofac. Surg.* 2007;36:916–21.

PARTICULARS OF CONTRIBUTORS:

1. Assistant Professor, Department of Oral and Maxillofacial surgery, Amrita Institute of Medical Sciences, Mangalore, India.
2. Professor, Department of Oral and Maxillofacial Surgery Amrita Institute of Medical Sciences, Mangalore, India.
3. Professor, Department of Oral and Maxillofacial Surgery, Yenepoya Dental College, Mangalore, India.
4. Professor and HOD, Department of Oral and Maxillofacial Surgery, Yenepoya Dental College, Mangalore, India.
5. Professor, Department of Oral and Maxillofacial Surgery, Yenepoya Dental College, Mangalore, India.
6. Professor, Department of Oral and Maxillofacial Surgery, Yenepoya Dental College, Mangalore, India.

NAME, ADDRESS, E-MAIL ID OF THE CORRESPONDING AUTHOR:

Dr. Mathew O Mampilly,
Mampilly House, Maria Villa, Narakkal - 682505, Kochi, India.
Phone : 9446038779, E-mail : mathewom@yahoo.com

FINANCIAL OR OTHER COMPETING INTERESTS: None.

Date of Submission: **Jun 25, 2014**

Date of Peer Review: **Jul 29, 2014**

Date of Acceptance: **Jul 31, 2014**

Date of Publishing: **Nov 20, 2014**