

Acute Kidney Injury in A Patient with Membranous Nephropathy – A Case Report

UDAY BANDE¹, VENKATESH MOGER², VASANTHA KAMATH³, MALLIKARJUNASWAMY⁴, CHANDRASHEKAR⁵

ABSTRACT

Acute Kidney Injury (AKI) is one of the most challenging problems faced by clinicians in the tropics owing to its fast-changing burden. Acute Kidney Injury is an important complication of membranous nephropathy. Causes are varied and include hypovolemia, crescentic conversion of preexisting nephropathy, renal vein thrombosis, NSAID'S, vasculitis, and sepsis. In this case report we discuss the case of membranous nephropathy in a young adult complicated by AKI. This report highlights the importance of early renal biopsy in patients with post GE AKI not improving on hemodialysis. Here we also discuss the potential differentials to be considered in a case of membranous nephropathy with AKI.

Key words: Acute Kidney Injury (AKI), Acute Tubular Necrosis (ATN), Gastroenteritis (GE), Nephrotic Syndrome (NS)

CASE REPORT

A 28-year-old male presented to the emergency department with history of breathlessness and decreased urine output. History of 20 episodes loose stools and 10 episodes of vomiting since the past 3 days. The stools were watery, non-foul smelling and the vomitus contained food particles.

Patient had sore throat 2 weeks prior to the episode. No history of pain abdomen, hematuria, fever, headache or seizures at the time of admission.

He was not a known case of diabetes, hypertension, epilepsy, asthma, cardiac or chronic kidney disease.

On examination--Pulse:110/min, regular, BP:170/110 mm hg, RR:34/min, regular, Spo2: 80% at room air, JVP: elevated. Pallor: present. There was no cyanosis, icterus, pedal edema or lymphadenopathy.

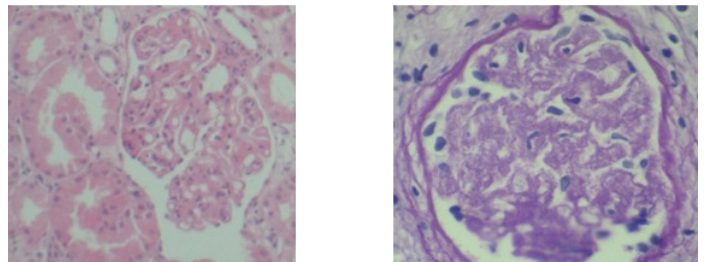
Respiratory system examination revealed bilateral basal crepts and rest of the systems were normal. Investigations – Complete hemogram: normocytic normochromic blood picture, ESR:10 mm in first hour, Serum creatinine: 11.6 mg%, urea: 140 mg%, LDH:200 IU/L.; Albumin 1.8 g/dl; WBC-- 10,000/ μ l. Urinalysis showed 1+ proteinuria, 10 leukocytes, hyaline casts and 3-5 RBC/hpf. Hemoglobin electrophoresis was within normal limits, Stool for hanging drop was negative for vibrio. ANA, ANCA were negative, C3- 0.92 (normal range 0.88-1.65) and C4- 0.38 (0.14-0.44); ASO titre - normal; HBsAg, anti-HCV and HIV were negative. Serum lipid profile was within normal limits.

Chest X-ray showed bilateral prominent vascular markings with normal cardiac silhouette. Ultrasound abdomen showed peripheral area of geographical infarct in the spleen. Right kidney -12.6 \times 5.1cm, left kidney 13.4 \times 6.5 with Grade 2 renal parenchymal changes, no calculi, and renal artery Doppler study was normal. CT abdomen was normal. Patient was given supportive treatment and 5 sittings of hemodialysis were done.

Urine output and renal indices of the patient did not improve after 20 days of hemodialysis. Renal biopsy was done. Histopathological examination of renal biopsy showed 4 viable Glomeruli of normal size with stiff round and patent non proliferative capillary loops all throughout & thick basement membrane. PAS staining showed

uniformly thickened capillary loops throughout [Table/Fig-1]. Fuschinophilic deposits were seen along the loops. Staining showed spikes in the basement membrane. Tubules showed diffuse acute tubular injury pattern with loss of tubular details and shedding of the epithelium into the lumen [Table/Fig-2]. There was mild hyperplasia of the tunica media. No necrotizing lesions, vasculitic foci, granulomas, crescent formation or eosinophils were seen. Immunoflorescence showed diffuse fine granular deposits of Ig G (3+) & C 3 (3+). There was no evidence of Ig A, IgM, C1q and light chains.

Patient was given course of steroids followed by cyclophosphamide as per modified Ponticelli protocol. His urine output and renal indices improved dramatically. Once his renal failure improved the proteinuria increased to 5.2 gm/day. Patient developed sagittal sinus thrombosis during follow up and was treated with anticoagulants.



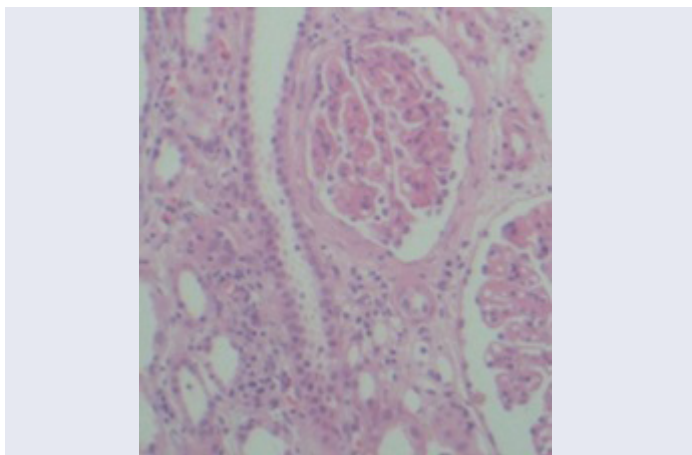
[Table/Fig-1]: H & E (left) and PAS (right) staining (\times 1000) shows thickened capillary loops & loss of tubular details with intra luminal shedding of epithelium

DISCUSSION

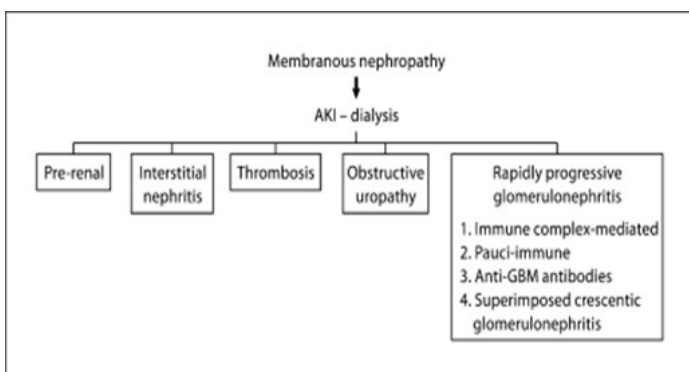
Sepsis due to bacterial invasion, parasitic and viral infections, toxins and acute diarrheal diseases are the most common causes of AKI in the tropics. In India AKI account for 6.4 cases per 1000 admissions [1]. In a patient with preexisting membranous nephropathy acute events mentioned below [Table/Fig-2] causes rapidly falling renal function requiring dialysis. AKI is a spontaneous complication of nephrotic syndrome.

The following [Table/Fig-3] shows the causes to be noted in such cases of rapid renal shutdown in membranous nephropathy.

Approximately 30% of children and adults [2-4] with idiopathic NS have a significant decrease in GFR. AKI reflects the worsening of this intrinsic problem.



[Table/Fig-2]: H & E staining ($\times 400$) shows diffuse tubular damage with thick capillary loops and medial hyperplasia of blood vessels



[Table/Fig-3]: Figure shows the causes to be noted in such cases of rapid renal shutdown in membranous nephropathy

Factors contributing to the decrease of GFR in NS patients include low renal perfusion pressure, decreased filtration fraction coefficient, high intra tubular pressure secondary to protein casts in heavy proteinuria or albumin infusions [5,2], ATN & interstitial edema [6].

Majority of adult patients with NS and coexisting AKI are elderly hypertensive's, have severe proteinuria and usually show renal recovery after an average period of 7 weeks [5,2]. Histological changes of ATN are present in 71% cases of AKI and NS [4]. Intimal hyperplasia and hyalinosis are important in the pathogenesis of AKI in such cases [1,6,4]. Biopsies of children with AKI and NS showed changes compatible with ATN [3,7].

Renal biopsy of the patient showed features of membranous nephropathy. Patient had history of upper respiratory tract infection in the preceding 2 weeks. Normal ASO titer and absence of crescents helped to exclude immune complex mediated disease [8]. USG and CT abdomen ruled out obstructive uropathy and renal vein thrombosis. Absence of rash and eosinophils ruled out interstitial nephritis as the cause of his acute decompensation. Absence of granulomas, vasculitic foci on renal biopsy ruled out small/medium vessel vasculitis in this patient [9,10,11].

Since there was history of diarrhea and most of all other differentials were either ruled out or had a low probability in this patient, we concluded that this case of membranous nephropathy was complicated by post GE AKI and both played their part in the renal dysfunction that ensued.

The case report highlights the need for early nephrological consultation in cases of post GE AKI with delayed resolution. Secondly, the report highlights the need for renal biopsy in such cases. Thirdly, the report highlights that in cases of nephropathy with AKI urinary, protein levels will be on the lower side. Finally, the report highlights the well known importance of renal biopsy in solving the diagnostic dilemma of NS patients presenting with AKI.

REFERENCES

- [1] Jha V, Chugh KS. Acute renal failure in the tropics. *J Assoc Physicians India*. 1997; 45:18–23.
- [2] Koomans HA. Pathophysiology of acute renal failure in idiopathic nephrotic syndrome. *Nephrol Dial Transplant*. 2001; 16:c221–c24.
- [3] Meadow SR, Cameron JS, Ogg CS, Saxton HM. Children referred for acute dialysis. *Arch Dis Childhood*. 1971; 46 :221-23.
- [4] Hull RP, Goldsmith JA. Nephrotic syndrome in adults. *BMJ*. 2008; 336:c1185–c89.
- [5] Smith JD, Hayslett JP. Reversible renal failure with nephrotic syndrome. *Am J kid dis*. 1992; 3:201-13.
- [6] Lowenstein JC, Falk RJ. Adult minimal change glomerulopathy with AKI. *Am J Kidney Dis*. 1990;5:432-37.
- [7] Sakarcan A, Timmons C, Seikaly MG. Reversible idiopathic acute renal failure in children with primary nephrotic syndrome. *J Pediatr*. 1994; 125:723-27.
- [8] James SH, Lien YH, Ruffenach SJ, Wilcox GE. Acute renal failure in membranous glomerulonephropathy: a result of superimposed crescentic glomerulonephritis. *J Am Soc Nephrol*. 1995; 6:c1541–c46.
- [9] *Nephrol Dial Transplant*. 2005 Jun; 20(6):1263-6.
- [10] Charney DA, Singh A, Aaron N. A male nephrotic patient with rapid decline in renal function. *Nephrol Dial Transplant*. 2005; 20:c1263–c66.
- [11] *Nephron Clin Pract*. 2010 June; 115(2): c100–c06.

PARTICULARS OF CONTRIBUTORS:

1. Associate Professor, Department of Gen Medicine, KIMS Hubli, Karnataka, India.
2. Associate Professor, Department of Nephrology, KIMS Hubli, Karnataka, India.
3. Director, Professor, Department of Medicine, KIMS Hubli, Karnataka, India.
4. HOD, Professor, Department of Medicine, KIMS Hubli, Karnataka, India.
5. Post graduate, Department of Medicine, KIMS Hubli, Karnataka, India.

NAME, ADDRESS, E-MAIL ID OF THE CORRESPONDING AUTHOR:

Dr. Uday Bande,
Associate Professor, Department of Medicine, KIMS, Hubli, Karnataka, India.
Phone: 9449340900, E-mail: udayphysici@yahoo.co.in

FINANCIAL OR OTHER COMPETING INTERESTS: None.

Date of Submission: **Jun 02, 2013**

Date of Peer Review: **Aug 01, 2013**

Date of Acceptance: **Aug 19, 2013**

Date of Publishing: **Oct 05, 2013**