

Caput Tertium Gastrocnemius: A Case Report

RAJAN KUMAR SINGLA, RIMPI GUPTA

ABSTRACT

Introduction: Caput tertium gastrocnemius is a rare but clinically important entity, as it may lead to the conditions of intermittent claudication, arterial stasis and aneurysm, venous stasis and impaired nerve function. In the recent years, it has gained more significance due to the advent of sports and the high stakes which are involved in this area. More cases of young athletes with popliteal artery entrapment are being seen. An early diagnosis is of great importance in order to avoid vascular complications and to aid in the early rehabilitation of the athletes.

Materials and Methods: The material comprised of the left lower limb of a male cadaver of approximately 50 years of age, which

was dissected during the routine undergraduate dissection by the usual method of dissection.

Results: A third head of the gastrocnemius was found to arise from the popliteal surface of the femur and the lower half of the medial supracondylar ridge. It passed superficial to the popliteal vessels and joined the medial head of the gastrocnemius. The two heads (the third and the medial) seemed to form a constricting circle around the popliteal vessels, putting the same even in more danger of entrapment.

Ontogeny: Such muscular variations may be due to our genetic composition, errors of the developmental timings or the persistence of some embryological conditions.

Key Words: Caput Tertium Gastrocnemius, Medial head of the gastrocnemius, Popliteal vessels, Entrapment syndrome

INTRODUCTION

The gastrocnemius is the most superficial muscle of the calf. It arises by two heads which are connected to the femoral condyles by strong flat tendons. The medial and the larger head is attached to a depression at the upper and the posterior part of the medial condyle, behind the adductor tubercle and to a slightly raised area on the popliteal surface of the femur, just above the medial condyle. The lateral head is attached on the lateral surface of the lateral condyle and on the lower part of the corresponding supracondylar line. Both the heads also arise from subjacent areas on the capsule of the knee joint. The fleshy part of the muscle extends to about midcalf, the muscle fibres of the medial head extending lower than those of the lateral head and inserting into a broad aponeurosis that develops on its anterior surface. The aponeurosis gradually contracts and receives the tendon of the soleus on its deep surface, to form the tendocalcaneus or the tendon of Achilles [1]. Variations of the gastrocnemius have been reported by earlier authors in the form of a sesamoid bone in the tendon of its lateral head or occasionally in the tendon of the medial head; the third head arising from the popliteal surface of the femur [1,2] the two heads being separable further down than usual; their tendon being perfectly separate from that of the soleus for a few inches; the lateral head having a few lower fibres attached to the external lateral ligament or the fibular collateral ligament (Posterior ligament of Winslow); and the entire muscle may be bi-laminar and the lateral head may be entirely tendinous [2] or absent [1,3]. Out of these, the third head (Caput Tertium) is the most common variation of the gastrocnemius [1,4].

CASE REPORT

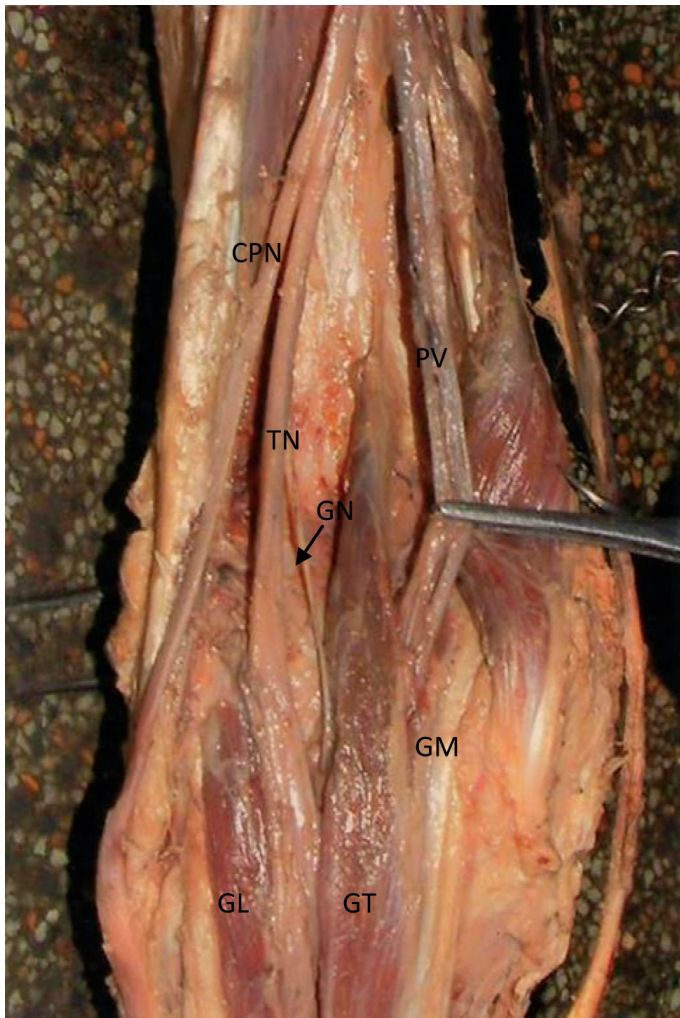
During the routine undergraduate dissection of the left lower limb of a male cadaver of approximately 50 years of age, the third head

of the gastrocnemius was seen. The muscle, along with its third head, was carefully cleaned, preserving its attachments, its relative position and its neurovascular relations. The third head of the gastrocnemius was found to arise from the popliteal surface of the femur and from the lower half of medial supracondylar ridge. Its belly was almost of the same size as that of the medial head. It passed superficial to the popliteal vessels and terminated by joining the medial head of the gastrocnemius. The two heads (the third and the medial) at their origin, seemed to form a constricting circle around the popliteal vessels. The third head received a branch from the tibial nerve on its deep aspect in its proximal part See [Table/ Fig-1]. No other variation or anomaly was encountered in the same limb or in the contralateral limb.

DISCUSSION

The variations in the muscles arise primarily due to our genetic composition, an inheritance which is carried over from our ancient origins. Many or most of the variations are totally benign; some are errors of the embryologic developmental timing or the persistence of an embryologic condition. Some of these variations may seriously compromise parts of the muscular, vascular, nervous, skeletal and/or other organ systems. It was the notion of Galen that the human body has been created in the best possible way, reflecting the perfection of the Creator, and that the variations were the result of an imperfect or unnatural development [5].

The gastrocnemius is frequently joined by a separate fascicle or a head which is known as the third head of the gastrocnemius (Caput tertium) and it has been studied extensively over a period of almost 200 years. Kelch (1813) [6] has been generally cited as the first to report the third head. It arises from some part of the popliteal surface of the femur. However, it may also arise from the linea aspera, the long head of the biceps femoris, the lateral



[Table/Fig-1]: Showing the Third Head of Gastrocnemius and Its Nerve Supply

(GL: Lateral head of gastrocnemius; GM: Medial head of gastrocnemius; GT: Third head of gastrocnemius; GN: Nerve to third head of gastrocnemius; PV: Popliteal vessels; TN: Tibial nerve; CPN: Common peroneal nerve.)

epicondyle, the knee joint capsule, the midfibula, and the crural fascia. The third head may “split” and arise from more than one location or divide near its termination to join both the heads of the gastrocnemius. It may or may not cross the popliteal neurovascular structures before its insertion into one head or the other, of the gastrocnemius or its tendon. It commonly joins the medial head of the gastrocnemius. Regardless of which head of the gastrocnemius it joins, its incidence as given by earlier authors [7,8,9], is shown in [Table/Fig-2].

Sr No.	Authors & year	Incidence (%)
1	Bergman et al, 1995 ⁷	2.9-5.5
2	Koplas et al, 2009 ⁸	1.9
3	Yildirim et al, 2011 ⁹	Isolated bilateral case

[Table/Fig-2]: Showing the incidence of Caput Tertium Gastrocnemius

ONTOGENY

Sharma et al., (2011) [10] threw light on the work of the earlier authors and commented that the gastrocnemius was the muscle of the fibular side of the leg. They proposed that it comes from the calcaneal blastomere and follows an ascending migration towards the inferior femoral epiphysis. The medial head inserts higher than the lateral one and comes in contact with the popliteal artery [11]. They further defined the third head as a congenital growth of the excess muscle. We assume that since this excessive muscle tissue

of the medial head in the present case could not pass completely on the medial aspect of the popliteal vessel; a part of it passed upwards from its lateral side and that this part constituted the third head. Its main attachment on the medial supracondylar line further supports our assumption that it is a part of the medial head.

CLINICAL SIGNIFICANCE

The third head may be a potential problem for the structures in the popliteal fossa [12]. It may lead to the conditions of intermittent claudication, arterial stasis and aneurysm, venous stasis and, and impaired nerve function before itself being discovered [13]. Iwai et al (1987) [14] blamed the third head of the gastrocnemius for the popliteal vessel entrapment syndrome. In the recent years, it has gained more significance due to the advent of sports and the high stakes which are involved in this area. More cases of young athletes with popliteal artery entrapment are being seen. An improvement in the investigative modalities has resulted in a more frequent diagnosis of this entity. An early diagnosis is of great importance in order to avoid vascular complications and to aid in the early rehabilitation of the athletes [10].

Depending upon the muscle which is responsible, the popliteal artery entrapment has been classified into 4 types by Dalaney and Gonzalez (1971) [15]:

- Type 1:** The most common type is where the popliteal artery courses medial to the medial head of the gastrocnemius which is inserted normally on the posterior aspect of the medial femoral condyle.
- Type 2:** The muscle (the third head) inserts abnormally on the posterior aspect of the femoral metaphysis, lateral to the normal insertion.
- Type 3:** An accessory tail to the gastrocnemius muscle separates the popliteal artery and the vein.
- Type 4:** The popliteal artery loops medially under the medial head of the gastrocnemius muscle; it passes deep to it and is compressed by the popliteal muscle.

In the types 1, 2 and 3, the medial head of the gastrocnemius and in type 4, the popliteal muscle as well, are responsible for the popliteal artery entrapment.

The gastrocnemius muscle in the present case did not fit into any of the above types. Here, the third head of the gastrocnemius was almost as bulky as the medial head; it had a reasonably long tendinous origin from the posterior surface of the femur and the left supracondylar ridge and it joined distally with the medial head; thus both the medial and the third heads encircled the popliteal vessels which were passing in between the two. So, when the two heads of the muscle (the medial and the third) contract, these could compress the popliteal vessels, leading to popliteal vessel entrapment and hence popliteal arterial and venous stasis and arterial aneurysm formation.

Thus, the authors suggest that another type 5 of the popliteal vessel entrapment be added to the above classification, with the following description:

- Type 5:** An anomalous third head of the gastrocnemius, almost the same size as that of the medial head, arising from the popliteal surface of the femur and/ or from the medial supracondylar ridge and joining the medial head; the two heads (the medial and the third) encircling the popliteal vessels.

This type of variation of the third head of the gastrocnemius will put the popliteal vessels even in more danger of entrapment, as

this along with the medial head forms almost a circle around the vessels.

REFERENCES

- [1] Salmon S. Muscle. In: Gray's Anatomy, the anatomical basis of medicine and surgery. Williams PL, Bannister LH, Berry M, Collin C, Dyson M, Dussek JE, Ferguson MWJ eds. 38th ed. Philadelphia, Churchill Livingstone. 1995; 884.
- [2] Macalister A. Observations on muscular anomalies in the human anatomy. Third series with a catalogue of the principal muscular variations hitherto published. Trans. Roy.Irish Acad. Sci. 1875; 25:1-130. Cited by Bergman RA, Afifi AK, Miyauchi R. Illustrated encyclopedia of human anatomic variation: Opus I: Muscular system: Gastrocnemius and Soleus. (URL: <http://www.anatomyatlases.org/>) (accessed on 17/12/2011).
- [3] Shepherd FJ. Notes on the abnormalities which were observed in the dissecting-room of McGill University, from October 1875 to May 1879. *Canada Med Surg J* 1880; 1:71-93.
- [4] Bergman RA, Afifi AK, Miyauchi R. Illustrated encyclopedia of the human anatomic variation: Opus I: Muscular system: Gastrocnemius and Soleus. (URL: <http://www.anatomyatlases.org/>) (accessed on 17/12/2011).
- [5] Gupta RK, Bhagwat SS. An anomalous muscle in the region of the popliteal fossa: A case report. *J Anat Soc Ind* 2006; 55(2): 65-8.
- [6] Kelch WG. Beiträge zur pathologischen Anatomie. 8, s.42, art. 36, Abweichung des Biceps Femoris. C. Salfeld, Berlin 1813. Cited by Bergman RA, Afifi AK, Miyauchi R. Illustrated encyclopedia of the human anatomic variation: Opus I: Muscular system: Gastrocnemius and Soleus. (URL: <http://www.anatomyatlases.org/>) (accessed on 17/12/2011).
- [7] Bergman RA, Walker CW, El-Khoury GY. The third head of the gastrocnemius in CT images. *Annals Anat* 1995; 177(3):291-4.
- [8] Koplak MC, Grooff P, Piraino D, Recht M. The third head of the gastrocnemius: an MR imaging study based on 1039 consecutive knee examinations. *Skeletal Radiol* 2009; 38(4): 349-54.
- [9] Yildirim FB, Sarikcioglu L, Nakajima K. The coexistence of the gastrocnemius tertius and the accessory soleus muscles. *J Korean Med Sci* 2011; 26(10):1378-81.
- [10] Sharma P, Arora A, Sharma RK, Salwan SK. Caput tertium gastrocnemius: its phylogenetic and clinical basis. *Int J App Biol and Pharmaceutical Technology* 2011; 2(4): 380-3.
- [11] Rosset E, Hartung O, Brunet C, Roche PH, Magnan PE, Mathieu JP, et al. The popliteal artery entrapment syndrome. Anatomic and embryologic bases and diagnostic and therapeutic considerations following a series of 15 cases with a review of literature. *Surg Radiol Anat* 1995; 17(2): 161-9, 23-7.
- [12] Frey H. Musculus gastrocnemius tertius. *Gegenbaurs Morphol. Jahrbuch* 1919; 50:517-30. Cited by Bergman RA, Afifi AK, Miyauchi R. Illustrated encyclopedia of the human anatomic variation: Opus I: Muscular system: Gastrocnemius and Soleus. (URL: <http://www.anatomyatlases.org/>) (accessed on 17/12/2011).
- [13] Hamming JJ. Intermittent claudication at an early age due to an anomalous course of the popliteal artery. *Angiology* 1959; 10:369-71.
- [14] Iwai T, Sato S, Yamada T, Muraoka Y, Sakurazawa K, Kinoshita H, et al. Popliteal vein entrapment caused by the third head of the gastrocnemius muscle. *Br J Surg* 1987; 74(11):1006-8.
- [15] Dalaney TA, Gonzalez LL. Occlusion of the popliteal artery due to muscular entrapment. *Surg* 1971; 69(1): 97-101.

AUTHOR(S):

1. Dr. Rajan Kumar Singla
2. Dr. Rimpi Gupta

PARTICULARS OF CONTRIBUTORS:

1. MS Anatomy, Additional Professor
Department of Anatomy,
Government Medical Colleg,
Amritsar-143001, Punjab, India.
2. MS Anatomy, Senior Lecturer,
Dashmesh Institute Of Research And Dental Sciences,
Faridkot, 151203, Punjab, India.

NAME, ADDRESS, E-MAIL ID OF THE CORRESPONDING AUTHOR:

Dr. Rajan Kumar Singla
79, S.G. Enclave,
Majitha Road,
Amritsar -143001, Punjab, India.
Phone: 9872477073, 08146669505
E-mail: rajananat@gmail.com

FINANCIAL OR OTHER COMPETING INTERESTS:

None.

Date of Submission: **Feb 04, 2012**
Date of Peer review: **Mar 28, 2012**
Date of Acceptance: **May 21, 2012**
Date of Publishing: **Aug 10, 2012**