

Advancement in Understanding and Treating Diabetic Foot Ulcer in Indian Scenario: A Comprehensive Review

MOHD SHAHID KHAN¹, NOOR JAHAN², RAZIA KHATOON³, FAISAL MOIN ANSARI⁴, SIRAJ AHMAD⁵

ABSTRACT

This advanced review focuses on preventing and managing Diabetic Foot Ulcers (DFUs), with a particular emphasis on the Indian context. It explores a range of strategies, including patient education, empirical therapeutics, advanced diagnostics like Polymerase Chain Reaction (PCR), and innovative treatments such as maggot therapy, Negative Pressure Wound Therapy (NPWT), Proximal Tibial Cortex Transverse Distraction (PTCTD), Platelet-rich Plasma (PRP), Leukocyte-Platelet-rich Fibrin (L-PRF), regenerative stem cell interventions, and novel applications like sucrose octasulfate dressings. The study underscores the critical role of patient education and timely interventions in preventing DFU complications. Advanced therapies, including maggot therapy, NPWT, PTCTD, PRP, and L-PRF, show promising results in expediting wound healing and reducing recurrence rates. Innovative approaches like antibiotic-loaded nano fibres and electrical stimulation offer new avenues for inhibiting bacterial growth and promoting wound healing. In summary, the prevention of DFU infections hinges on the trifecta of patient education, empirical therapeutics, and scrupulous wound management. Advanced therapeutic modalities offer a frontier of exciting possibilities for refining outcomes, particularly in regions like India with its unique infection profiles. This multidisciplinary tapestry, interwoven with emerging technologies, holds great potential for elevating the management of DFUs and ultimately enhancing the quality of life for those afflicted by this ailment. This advanced study represents the vanguard of DFU research, offering insights into pioneering strategies that warrant further exploration through rigorous research and large-scale clinical trials, thereby guiding the evolution of DFU management practices.

Keywords: Antimicrobials, Biofilms, Diabetes mellitus, Dressings, Emerging therapies, Ulcer grades

INTRODUCTION

In the last two decades, Diabetes Mellitus (DM) has gained global attention, characterised by persistent hyperglycaemia [1]. The preponderance of DM primarily manifests as Type 2 Diabetes Mellitus (T2DM), encompassing over 90% of cases. Regrettably, a staggering proportion exceeding 50% of individuals afflicted by T2DM persist in an undiagnosed state. The distinctive “Asian Indian Phenotype,” characterised by heightened abdominal adiposity, augmented waist circumference, and a paradoxically diminished Body Mass Index (BMI), renders individuals of Asian Indian descent disproportionately predisposed to DM [2]. The DM carries various complications that reduce life expectancy and negatively affect the Quality of Life (QoL) [3]. A Diabetic Foot Ulcer (DFU) is an open sore or wound that most likely occurs at the bottom of the foot or toes where repetitive trauma and pressure are encountered. It is the major complication of uncontrolled DM associated with a high degree of morbidity and mortality [4].

A severe consequence of diabetes is DFU, linked to Peripheral Artery Disease (PAD) and lower leg neuropathy. DFUs- neuropathy, ischaemia, infection- are aggravated by metabolic impairment, reducing peripheral blood flow, angiogenesis, and cell response, leading to complications such as gangrene, ulcers, anomalies, Peripheral Arterial Disease (PAD), and nerve damage [5]. DFUs often arise in pressure-prone foot regions, potentially causing osteomyelitis and amputations [6]. The prevalence of DFUs is significant, affecting 25% of diabetics over their lives, causing nearly 1 million foot amputations worldwide, with a global DFU-related limb amputation occurring every 20 seconds [7,8]. DFUs are 6.3% more common in men and more prevalent in T2DM. DFUs have a substantial recurrence risk- nearly 40% within a year and 65% within three years [1]. Preventing foot infections and injuries is vital in mitigating diabetes and DFU repercussions. Patients need empirical therapy and foot care education to avert infections. Topical antibiotics efficiently treat foot infections. Even clinically healthy

wounds face worsened prospects due to microbiota, particularly pathogenic strains [7]. Managing DFU demands a multidisciplinary approach and specialised diagnostics, suggesting new treatment norms and patient education. Polymerase Chain Reaction (PCR) for 16S ribosomal Deoxyribonucleic Acid (DNA) analysis offers precise insights into DFU microflora [8]. The DFU traits encompass wound features, regional antibiograms, tailored antimicrobials, frequent debridement, continuous assessment, and regular dressings [8]. The prevalence of diabetes is increasing, with an estimated 537 million adults recently affected. By 2045, the International Diabetes Federation (IDF) predicts 783.2 million individuals aged 20 to 79 with diabetes, mainly in middle-income countries [9]. The effect of Coronavirus Disease 2019 (COVID-19) on diabetes and its complications remains uncertain [10]. The DFU incurs high nursing expenses, 49.6% more than diabetes patients without DFU [11]. The IDF closely monitors DFU due to its substantial toll on patients' finances, physical health, and mental well-being [12].

This review spotlights the enhanced antimicrobial strategies- wound dressings, ulcer debridement, topical antibiotics, and cellular, gene, and molecular treatments. Rapid technological shifts challenge research and healthcare, underscoring comprehensive DFU analysis for future guidance.

MATERIALS AND METHODS

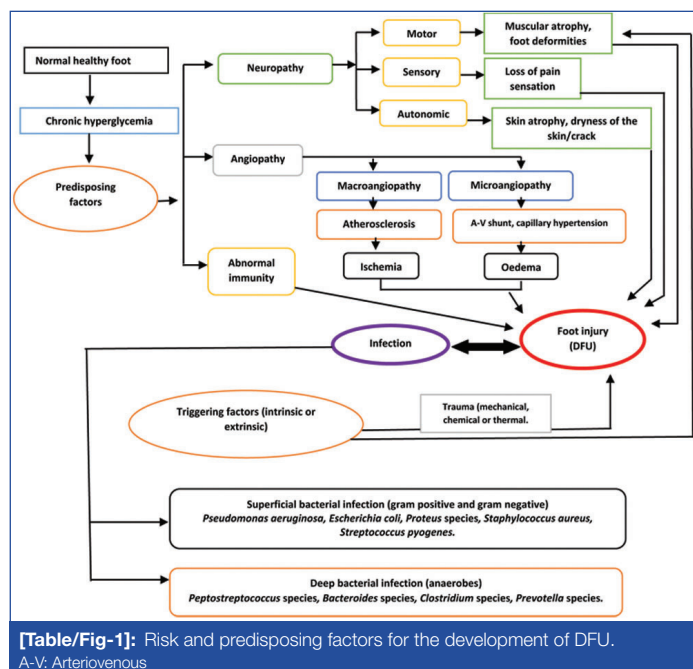
In this comprehensive review article, an extensive search was conducted spanning from January 2015 to July 2023, across five prominent electronic databases: PubMed, Science Direct, Embase, Web of Science, and Scopus. The focus was exclusively on English language articles, employing a meticulous set of keywords including “DFU”, “recent wound management”, “debridement”, “dressings types”, and “emerging therapies”.

Inclusion criteria encompassed diverse study designs such as Randomised Controlled Trials (RCTs), case-control studies, cohort

studies, prospective and retrospective studies, cross-sectional studies, and comprehensive review studies. Case reports and case series were intentionally excluded to maintain the rigor of review analysis. Additionally, a thorough examination of the bibliographies of all retrieved and pertinent publications was conducted to unearth any supplementary studies of relevance. This meticulous approach ensured a comprehensive and up-to-date overview.

Pathophysiology and Predisposing Factors

The aetiology of a DFU is multifaceted. Multiple risk factors are responsible for the development of DFU, as mentioned in [Table/Fig-1].



The DFUs result from the interplay of PAD, diabetic neuropathy, and immune dysfunction. Diabetic neuropathy diminishes pain and pressure perception in 80% of diabetics, fostering ulcers and anatomical anomalies like Charcot foot and hammertoes [1]. Regular neuropathy assessment is pivotal, involving tests for small and large fibres- pinprick, temperature sensing, vibration perception, and the 10 g monofilament test- to detect complications [13].

The PAD, impacting nearly half of DFU patients, markedly escalates adverse limb event risks. Evaluation of vascular symptoms like claudication, leg fatigue, and reduced exertion capacity is essential. Perfusion assessment involves palpating peripheral pulses and gauging extremity appearance and warmth. Ankle-brachial Index (ABI) testing is advisable, usually ranging from 0.9 to 1.3 (above 1.0). However, a high ABI with vascular calcifications may lead to inaccuracies. Evaluating Toe-brachial Index (TBI) along with arterial Doppler and ABI can aid PAD assessment. Triphasic Doppler patterns, TBI at 0.75, and ABI within 0.9-1.3 suggest an unlikely PAD diagnosis [14]. Microvascular blood flow impairment can be detected via laser Doppler flowmetry even if macrovascular aspects are intact [15].

Furthermore, DM compromises cellular-level immune function, heightening infection susceptibility [16]. Immunological dysfunction involves T lymphocyte apoptosis, pro-inflammatory cytokines, impaired cell function, and reduced epidermal cell migration [17]. Elevated blood glucose fosters bacteria, particularly aerobic Gram-positive strains. Diabetes-related structural/metabolic inadequacies impact fibroblasts, carbohydrates, collagen formation, and intensifying complications [18].

Infection of Diabetic Foot Ulcer (DFU)

The DFU infections substantially elevate amputation and mortality risks. For DFUs, microbial invasion is the main cause of foot infection

development, accounting for 80% of non traumatic lower-extremity amputations. Remarkably, 50% of DFUs are already impaired at diagnosis [7]. The wound microbiome significantly influences infection progression [19]. Microbiota presence and interaction are pivotal. Infections manifest with over 10^5 bacteria per gram of tissue. Dormant skin commensals can colonise uninfected DFU wounds due to delayed immune activation [20]. Susceptibility to infection is heightened by ischaemia, neuropathy, oedema, inflammation, and compromised immunity [21]. Infectious Diseases Society of America (IDSA) guidelines assess ulcer infection presence. Clinical evaluation revealing ≥ 2 symptoms- inflammation, indurations, perilesional erythema, hyperaesthesia, pain, local warmth, and purulent exudate- implies infection [22]. Around 78% of PAD patients are DFU cases. Endothelial dysfunction, particularly nitric oxide-related vasodilator reduction, heightens microcirculation impairment, intensifying ischaemic risk and ulceration [7].

Microbial Distribution of DFU in India and Globally

The microbial landscape within DFUs exhibits a complex and diverse composition influenced by a myriad of factors, including the host's physiological and pathological characteristics as well as the immune response. DFUs are often characterised by polymicrobial infections, comprising a spectrum of Gram-positive, Gram-negative, anaerobic bacteria, and specific fungi [21,23]. However, monomicrobial ulcers also prevail within the DFU spectrum [24,25]. In the realm of Diabetic Foot Infections (DFIs), Gram-negative bacteria exhibit a notable predominance over Gram-positive counterparts [23]. The distribution of these microbes within the wound ecosystem demonstrates distinct patterns, with aerobic bacteria predominantly inhabiting the wound surface, while anaerobic bacteria flourish in the wound's oxygen-deprived interior [7]. Commonly isolated Gram-negative bacterial culprits encompass *P. aeruginosa*, *E. coli*, *K. pneumoniae*, *Proteus* species, *Enterobacter* species, and *Citrobacter* species [26]. Conversely, *S. aureus*, in conjunction with *Enterococcus* species and *Streptococcus* species, stands as the most frequently encountered Gram-positive bacterial inhabitant within DFUs [27].

Geographical Factors and Microbial Variations

The geography in which DFUs manifest plays a pivotal role in shaping the microbial tapestry. Remarkable regional disparities exist in the prevalence of distinct microbial agents, accentuating the multifaceted nature of DFU microbiomes. In certain geographical contexts, Gram-negative bacteria, including *P. aeruginosa*, *E. coli*, and others, take centre stage, with Asia and Africa exhibiting higher propensities for these pathogens. In contrast, Western and Middle Eastern countries often witness the dominance of Gram-positive bacteria like *S. aureus* [23,28-30].

For instance, the Indian subcontinent showcases a diverse microbial profile within DFUs. Various regions across India report diverse bacterial prevalence, with Karnataka, Uttar Pradesh, Jammu, and Maharashtra spotlighting Gram-positive bacteria, notably *S. aureus*, as the primary causative agents [24,31-33]. Multiple authors have reported that in Central and North-eastern India, which have high temperatures and moderate humidity levels, Gram-negative bacteria such as *P. aeruginosa*, *E. coli*, and *K. pneumoniae* predominate [26,34,35].

Furthermore, meticulous sampling techniques have unveiled a notable incidence of monomicrobial DFI throughout the nation [26,28]. This intricate interplay of geography, climate, and microbial distribution underscores the need for region-specific approaches in the management and treatment of DFUs, acknowledging the diverse microbial ecosystems that prevail globally.

Biofilm and Multidrug-resistant Phenotypes in Diabetic Foot Ulcers (DFUs)

In the intricate landscape of DFUs, a pivotal player emerges- biofilm. This highly structured polysaccharide matrix encapsulates the

microbiota within DFUs, orchestrating a symphony of challenges. Biofilms significantly contribute to the chronicity of these lesions, foster the ascent of antibiotic resistance, and prolong the ulcers' prognosis due to immunological dysfunction. Within the biofilm arena, both Gram-positive and Gram-negative bacteria exhibit the capability to craft these tenacious structures. However, the prevalence of biofilm formation varies among bacterial species. *S. aureus* reigns supreme in this domain, with a prevalence rate of 38.8%. In contrast, *P. aeruginosa*, *Citrobacter* species, *E. coli*, and *Proteus* species exhibit a lower proclivity, each standing at 10.5%, while various other bacteria also partake in this intricate biofilm dance [24]. Within the context of DFUs, biofilms are a precipitating factor, synergising with neuropathy, trauma, altered foot anatomy, and protective barrier disruptions to perpetuate the wound's complexity [7].

The spectre of drug-resistant bacteria casts a formidable shadow over the realm of DFUs. The genesis of Multidrug-resistant Organisms (MDROs) within DFUs is an ominous consequence of worldwide antibiotic mismanagement. The trifecta of overuse, underuse, and irrational prescriptions has paved the way for the emergence of these resilient pathogens. It is imperative to exercise caution and prudence by refraining from the indiscriminate application of empirical antimicrobial therapy when microbial infection remains unconfirmed. Instead, a judicious approach is essential, with empirical antimicrobial therapy deployed as the first line of defence, only when necessary. Before resorting to broad-spectrum antibiotics, the performance of antimicrobial susceptibility testing is paramount, adhering to guidelines issued by authoritative bodies such as the Clinical and Laboratory Standards Institute (CLSI) [36]. It is imperative to recognise that empirical treatment bears no relevance in the prophylaxis or expeditious wound healing of non-infected diabetic feet.

Across South India, a disconcerting reality emerges, with 66% of DFU patients harbouring MDROs, encompassing 153 out of 279 bacterial isolates categorised as Multidrug-resistant (MDR) [37]. In Northwest India, heightened resistance takes root in Gram-negative bacteria, featuring Extended-spectrum Beta-lactamase (ESBL) and AmpC enzymes, afflicting 56% of individuals grappling with DFIs [38]. A distinct narrative unfolds in North-East India, where 61% of samples exhibit Gram-negative isolates, alongside 39% of Gram-positive counterparts. Remarkably, 53% of all Gram-negative samples within this cohort produce ESBLs. Methicillin-resistant *Staphylococcus aureus* (MRSA) assumes prominence, accounting for 41% of Gram-positive cases, while vancomycin-resistant *Enterococci* constitute 19% [35]. The highly resistant profile exhibited by bacterial isolates within DFUs is rooted in the realm of inappropriate antibiotic stewardship and the unwarranted use of broad-spectrum antibiotics. This unfortunate trajectory has propelled the survival of superbugs. Research emanating from China casts a revealing light, exposing a staggering 51% prevalence of MDROs among 475 bacterial strains. Pronounced resistance is observed across various microbial families, including Enterobacteriaceae, *P. aeruginosa*, *Acinetobacter baumannii*, *Streptococcus* species, and *Staphylococcus epidermidis* [39]. Bangladesh reports bacterial isolates frequently resistant to monobactam and third-generation cephalosporin antibiotics [40]. A comprehensive study in Ethiopia further underscores the gravity of the situation, with a staggering 92.9% of Gram-positive isolates (*S. aureus* and *Enterococcus* species) exhibiting MDR, including resistance to a spectrum of antibiotics [23].

The consequences of MDRO-infected DFUs are grave, marked by an elevated incidence of lower limb amputations. Several contributory risk factors, including ischaemia, larger ulcer dimensions, higher ulcer grading, osteomyelitis, premature empirical therapy, and hospitalisation, collectively fuel the proliferation of MDROs within DFUs [41]. Furthermore, DFU infections linked to MDR bacteria bear the burden of higher mortality rates, increased amputation rates, and extended hospital stays [35,42]. In the light of these harrowing

trends, the imperative for judicious antibiotic use and rigorous infection control measures in managing DFUs and combating the ascent of MDROs is unequivocal.

Diagnosis of Diabetic Foot Infection

Microbiological and molecular approaches are the two methods used for diagnosing DFIs.

Diagnostic Microbiological Approach

It is crucial to identify the cause of DFUs in order to administer appropriate and precise antibiotic therapy. To achieve this, sufficient sampling must be conducted to avoid contamination by commensal flora. Typically, four different methods are used to collect samples from superficial and deep tissue wounds. These methods include needle aspiration, tissue biopsy, bone biopsy, curettage following debridement, and swabs from superficial ulcers (Grades 0, 1, and 2) using Levine's approach.

The most beneficial and favoured method of sampling in Grade 3, 4, and 5 DFUs is tissue and bone biopsy, but it is a delicate process with the risk of infectious growth. Therefore, it should be performed by a qualified technician or therapist. Wound swab cultures frequently do not match tissue cultures well and often result in the irrational use of antibiotic therapy, leading to the emergence of MDR and Pan-drug Resistant (PDR) bacterial strains. To prevent this issue, appropriate sample collection techniques should be employed [42].

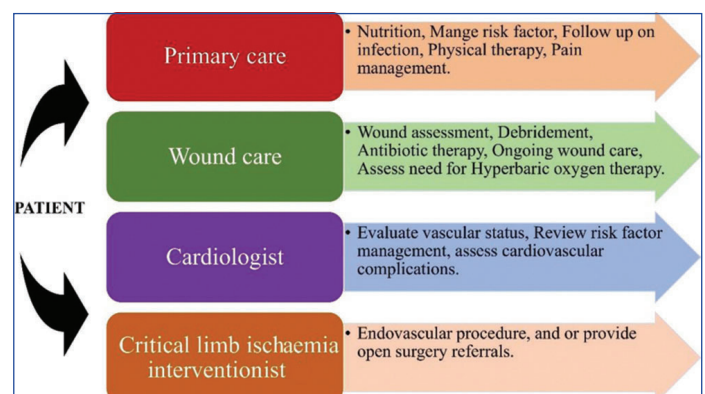
Molecular Approaches

Molecular diagnosis is a powerful tool for identifying the microbiomes of chronic wounds. With the discovery of the 16S ribosomal DNA sequence, which is unique to bacteria and referred to as the universal primer, gene sequencing has become one of the most recent and highly sophisticated techniques in this field for the culture-free process of microbial identification. A comparison is then made with the virtual library of bacterial genomic sequences, which includes flanking sequences for the target.

Compared to traditional identification processes, molecular diagnosis is more accurate, precise, and quick. Therefore, the diabetic community should embrace it for an accurate microbial assessment of diabetic foot infection [43].

Management

The management of DFUs involves a multidisciplinary approach, particularly in developing countries with high illiteracy and poverty rates, where awareness and preventive measures are lacking. Proper management of DFUs can significantly prevent complications such as foot infections, gangrene, amputations, and mortality. A multidisciplinary team, consisting of endocrinologists, dieticians, vascular surgeons, infectious disease specialists, dermatologists, and nurses, is essential for achieving favourable outcomes in DFU cases [Table/Fig-2] [44]. Studies have shown that multidisciplinary teams have reduced major amputations in DFU patients. Implementing



[Table/Fig-2]: Diagram showing the role of each member of multidisciplinary team to prevent amputation.

strict glycaemic control, local wound management, vasculopathy, and infection management in a coordinated manner can effectively reduce major amputations [45]. Clinical and economic outcomes in Asian populations have demonstrated a decrease in both minor (14% to 3%) and major (9% to 3%) amputations with the use of multidisciplinary teams [46].

In the present paper, review evaluate all the information currently available on managing DFUs, including education, regulation of blood sugar, debridement, dressing, topical antimicrobials, systemic antimicrobial therapy, and advanced emerging therapies that are currently employed in clinical practice.

Education

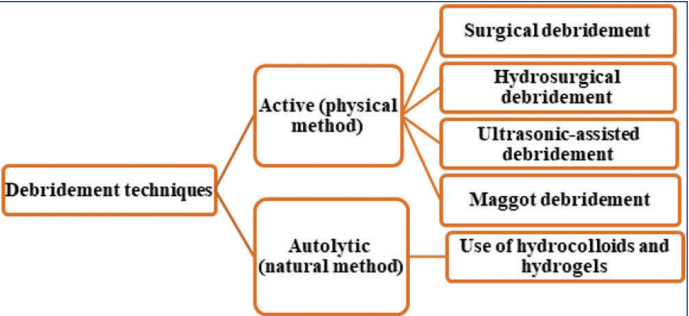
Effective education can prevent DFI up to 49-85% [47]. Self-management is considered the cornerstone in preventing foot infections. The patient education programme needs to emphasise the patient’s responsibility to take care of their feet by regularly inspecting them, practicing proper cleaning and foot hygiene, using appropriate socks and footwear, monitoring foot temperature, and being vigilant for any signs of inflammation to prevent ulcers and amputation [31].

Blood Sugar Control

The key factor in DFU, which results in delayed wound healing and imposes a significant strain on the economy, is inadequate blood sugar control [6]. The HbA1c test is the best method for determining average blood glucose levels over three months. Studies have shown that elevated blood glucose levels are associated with suppressed inflammatory responses, which impair the host’s immune response to infection [44]. Compared to patients with blood glucose levels within the regulated range (110 mg/dL), patients with blood glucose levels between 110 and 200 mg/dL and those with levels exceeding 200 mg/dL had 1.7- and 2.1-fold higher fatality rates, respectively. Moreover, studies have reported infection rates 2.7 times higher in patients with higher blood glucose levels (>220 mg/dL) compared to those with lower levels [48]. Additionally, a 1% decrease in mean HbA1c was found to be associated with a 25% decrease in micro-angiopathy complications, notably neuropathy. Conversely, a 1% increase in HbA1c was found to increase the relative risk of developing PAD, one of the primary causes of DFU, to 25-28% [44].

Debridement

Debridement [Table/Fig-3] is one of the crucial procedures in the management of DFU infection. It involves the removal of microbiota-producing biofilm and necrotic tissues, which facilitates a complete assessment of the ulcer, provides tissue for diagnostic microbiological procedures, and enhances prophylaxis [49,50].



[Table/Fig-3]: Flowchart showing debridement techniques [50].

A recent review article on the management of DFUs compared enzymatic debridement using Clostridial Collagenase Ointment (CCO) to standard care plus hydrogel debridement. The study observed no difference in wound size at two different time intervals, namely 6 weeks and 12 weeks [51,52].

Dressings

Wound dressing is done to protect the infected area from direct environmental exposure and further inoculation. It also helps restore moisture, which facilitates autolytic debridement through endogenous proteolytic enzymes and enhances wound healing [51]. High-secretory wounds require good absorbent dressings, while non secretory wounds require moisture balance dressings that sustain moisture to accelerate wound healing. [Table/Fig-4] enlists various dressing types for the management of DFUs [8,43,51,53,54].

Type of dressing	Function	Drawback	References
Nano-silver dressing	It's a novel broad-spectrum antibacterial wound dressing which facilitates better drainage, restores moisture, kills bacteria, reduces odour while releasing silver ions. It also enhances the wound healing rate and alleviates pain to some extent.	Imprudent use of this can lead to impaired healing of wound, and in high concentration, it can be toxic to fibroblast cells.	[8,53]
Alginate dressing	Absorb wound exudates maintain a moist environment, haemostatic and flexible.	It cannot be used on hardened eschar, can produce an anaphylactic reaction, removal from the wound is difficult and is not used in anaerobic infection.	[51,54]
Hydrogel	It includes an insoluble copolymer, maintains a moist environment, facilitates autolytic debridement, and has a soothing and cooling effect on the skin, enzymes lactoperoxidase and glucose oxidase provides antibacterial action.	It cannot be used in high exuding wounds and may cause allergic reactions in older people.	[51,54]
Acrylics	This is a thin clear film permeable to water vapour with low absorbance capacity.	Poor absorbance of exudates with removal difficulties.	[43,51]
Hydrocolloids	It consists of a hydrophilic carboxy component and hydrophobic methylcellulose bound to a polyurethane film, facilitates angiogenesis, granulation, and autolytic debridement, provides an acidic environment to inhibit bacterial growth, reduces pain and is self-adherent and long-wearing.	Not recommended on clinically infected wounds, it may facilitate the growth of anaerobic bacteria removal can be painful and can disturb the wound with an allergic reaction.	[43,54]
Foam adhesive	Composed of polyurethane with variable pore sizes which serves as a filter for silver and ibuprofen onto the wound and provides thermal insulation.	Induce maceration in the surrounding skin.	[43,54]
Hydro fibres	Composed of carboxy methylcellulose sheets with high absorptive capacity, facilitates autolytic debridement and is easy to remove.	Secondary dressing is required.	[43,54]

[Table/Fig-4]: Dressing types widely used in the management of DFU [8,43,51,53,54].

Negative Pressure Wound Therapy (NPWT)

Wound dressing is a critical aspect of managing DFUs. One effective approach is NPWT, which involves the application of sub-atmospheric pressure to the wound using a vacuum-sealed dressing. NPWT promotes wound healing by creating a controlled environment that removes excess exudate, reduces oedema, and enhances perfusion. It also stimulates granulation tissue formation

and promotes wound contraction, thus accelerating the overall healing process [51]. NPWT is particularly beneficial for high-secretory wounds as it helps maintain a clean and moist wound bed conducive to autolytic debridement by endogenous proteolytic enzymes [55].

Offloading Techniques

Pressure offloading is a critical component in the healing of DFUs. Offloading involves reducing or eliminating pressure on the wound area to allow for proper healing. Frequent trauma and high plantar pressure on ulcer beds are major reasons for the chronicity of DFUs once they develop. Various offloading techniques are available, including Total Contact Casts (TCC), removable cast footwear, wedge footwear, and half shoes. Among these, the TCC is considered the gold standard method for offloading DFUs with neuropathy. Another innovative offloading device, the Vaco cast diabetic, provides pressure relief to the forefoot and midfoot ulcers while allowing the patient to maintain a normal gait with its rocker sole. Unlike TCC, the Vaco cast diabetic allows easy assessment of the wound by unlocking the device [56]. Studies have shown that properly offloaded DFUs can heal in approximately six weeks in about 90% of cases [57].

Use of Antiseptics

Antiseptics or topical antimicrobial ointments are not considered the preferred treatment for chronic wounds like DFUs. This is because they can disrupt the moisture balance required for effective autolytic debridement and may lead to contact dermatitis. Moreover, excessive and repeated use of antiseptics on wounds without proper indication and information may result in an impaired outcome or favour the development of a microbiome similar to chronic wounds. With the emergence of polymicrobial biofilms and the discovery of bacterial strains resistant to antiseptics, the role of topical antimicrobials/antiseptics is doubtful and questionable. In line with this, international guidelines do not suggest the routine use of antiseptics in the management of DFU [58]. If used, antiseptics should be selected based on low toxicity to host tissues. Commonly used antiseptics for DFUs include povidone-iodine (10% solution), chlorhexidine, acetic acid 5%, sodium hypochlorite, and cadexomer iodine [59,60].

Antibiotic Therapy

According to IDSA, DFU patients with mild infections can be treated in an outpatient setting with oral antibiotics that mainly cover Gram-positive commensal flora of the skin, such as *S. aureus* and *Streptococcus* species. Effective choices for antimicrobials include cephalexin, dicloxacillin, amoxicillin-clavulanic acid, or clindamycin. In cases of suspected MRSA infection, specific antibiotics like clindamycin, linezolid, trimethoprim-sulfamethoxazole, or minocycline may be considered. For infections involving Gram-negative bacteria, combination therapy may be used, such as amoxicillin-clavulanate plus trimethoprim-sulfamethoxazole or clindamycin plus fluoroquinolone.

For moderate to severe infections, hospitalisation for parenteral antimicrobial therapy is advised. Empirical therapy should involve broad-spectrum antibiotics that cover both Gram-negative and Gram-positive bacteria causing DFUs, including *S. aureus*, MRSA, *Streptococcus* species, aerobic Gram-negative bacteria (*E. coli*, *Klebsiella* species, or *P. aeruginosa*), and anaerobes. If MRSA is suspected in moderate to severe wound infection, vancomycin, linezolid, or daptomycin should be considered for empirical therapy. For aerobic and anaerobic Gram-negative bacteria, acceptable choices for empirical antimicrobial therapy include ampicillin-sulbactam, piperacillin-tazobactam, ertapenem, or meropenem. Alternatively, cefepime, ceftriaxone, moxifloxacin, levofloxacin, or aztreonam plus metronidazole would be adequate to provide coverage for both.

The course of treatment should be personalised-based on the type and grade of the DFU. For outpatients on oral therapy, the duration should be restricted to 1-2 weeks. For those treated parenterally but without osteomyelitis, 2-4 weeks are generally sufficient. Prolonged therapy is required for patients with grade 3 ulcers (involving osteomyelitis), with a minimum duration of 4-6 weeks. The course of treatment may be shorter for patients who undergo amputation as part of the treatment regimen [61].

However, for precise and rational use of antibiotics and to prevent the emergence of MDR strains, the course of treatment and the antimicrobial agent employed should be determined based on the results of microbiological culture and antibiotic susceptibility testing, the clinical presentation, and the patient's immune level. Starting with a broad-spectrum antibiotic as empirical therapy is common in practice, but clinicians should transition to a specific drug once the bacterial culture report is available. Hospitalisation is necessary for severe infections involving deeper tissue and bone infections [39].

Surgery

Surgical procedures play a crucial role in the management of DFU and have been widely adopted over the past few decades. Surgery for DFU management includes vascular foot surgery, non vascular foot surgery, and, in severe cases, amputation as a last resort [44].

Vascular foot surgery: This involves bypass grafts and peripheral angioplasty to improve blood circulation in the ischaemic foot.

Non vascular surgery: Non vascular surgeries are divided into four categories, namely elective, prophylactic, curative, and emergent surgeries, and are mainly performed to decrease plantar pressure by correcting foot deformities.

Amputation: Amputation is considered a last resort for DFU management and is indicated for the removal of gangrenous tissue in ulcer grades 4 and 5, and to control infection.

Numerous novel therapies are being developed to enhance the healing of ulcers, reduce the number of amputations, and improve overall outcomes. These emerging therapies differ from the conventional treatments involved in the management of DFUs and include inflammatory modulators, blood products, adjuvant growth factors, herbal extracts, and hyperbaric oxygen therapy. Foot hygiene and care remain essential components of effective DFU management [7]. Enhanced adjuvant treatment is highly favoured in the current treatment plan, and biological therapy, such as Platelet-Rich Plasma (PRP) and recombinant growth factors, are used to treat resistant ulcerations.

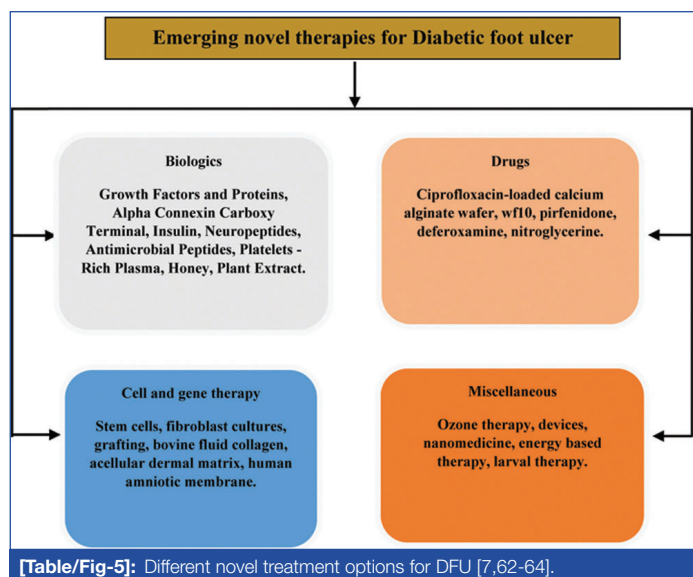
In the present scenario, stem cell therapy has emerged as a good treatment option. Immunomodulation, angiogenesis, neuro-regeneration, cell recruitment, and extracellular matrix remodelling are all favoured by stem cell cytokines and help in wound recovery and tissue regrowth. The types of stem cells used include:

1. Myofibroblasts
2. Keratinocytes
3. Pericytes
4. Endothelial cells

There are several novel treatment options for DFU patients that have been published in various literature sources as shown in [Table/Fig-5] [7,62-64].

Recent Advances in the Field of DFU Treatment

Medical-grade maggots are deliberately utilised in treating chronic wounds by employing *Chrysomya megacephala* larvae. These maggots aid in eliminating necrotic tissues and infections, promoting tissue granulation, and enhancing wound healing, making them an alternative to traditional debridement methods. Moreover, combinational therapies involving maggot treatment, surgical debridement, silver dressing, and NPWT have shown promising prophylaxis in chronic DFU patients with MDR infections.



A prospective randomised study conducted by Maranna H et al., on 45 DFU patients compared the efficacy of NPWT and saline dressing. Group A, receiving NPWT, exhibited an early reduction in ulcer size, more granulation tissue formation, and shorter hospital stays with complete wound healing compared to Group A, which received saline dressings [62]. Wang N et al., conducted a comparative meta-analysis and concluded that NPWT accelerates wound healing and minimises the risk of future amputations compared to Moist Wound Care (MWC) [63]. Patients with chronic DM and microangiopathy benefit from improved microvascular function through repeated transcutaneous CO₂ infusion treatment without systemic adverse effects [64].

Proximal Tibial Cortex Transverse Distraction (PTCTD) has emerged as a promising method for treating DFUs. It facilitates rapid wound recovery and limb salvage by enhancing neovascularisation and perfusion in ulcerated feet through Stromal Cell-derived Factor-1 (SDF-1). Additionally, SDF-1 supports osteogenesis during bone displacement and plays a crucial role in the migration of Endothelial Progenitor Cells (EPCs) and Bone Marrow-derived Mesenchymal Stem Cells (BMSCs) [65]. PTCTD effectively eliminates recurrence in exaggerated and recalcitrant DFUs.

The PRP acts as a growth factor ligand and possesses mitogenic and chemotactic qualities that expedite wound healing. Although it is common, PRP preparation remains expensive and time-consuming. Studies have yielded conflicting results regarding the efficacy of PRP dressing compared to normal saline dressing in conjunction with TCC, necessitating large-scale, well-designed trials for re-evaluation [57,66,67].

Leukocyte-Platelet-rich Fibrin (L-PRF) is expected to be widely adopted due to its efficiency, economy, and simplicity as a DFU treatment adjuvant. Its fibrin network serves as a biological matrix for tissue regeneration and controlled growth factor release over a 1-2-week interval. Combining L-PRF with hyaluronic acid shows superior results, promoting accelerated angiogenesis and reducing the inflammatory pathway [68].

Allogenic adipose-derived stem cell injection into DFUs has been found to be safe and effective, reducing recurrence and amputation rates, and improving patients' QoL. Although expensive, this procedure proves to be a cost-effective long-term investment in overall health and labour costs.

He S et al., conducted a clinical trial on DFU patients using Continuous Diffusion of Oxygen (CDO) in combination with conventional Moist Wound Dressing (MWD). The combination facilitated early wound healing, reduced infection rates, and lowered inflammatory markers, such as C-reactive Protein (CRP). Additionally, no amputations were recorded in the combinational group [69].

For chronic neuropathic ulcers, a novel sucrose octasulphate-impregnated dressing inhibits Matrix Metalloproteinase (MMP) action, promoting proper healing. Clinical trials have shown statistically significant advantages in using these dressings [10].

Placenta-derived products containing epithelial cells, neonatal fibroblasts, and BMSCs, along with various growth factors and a collagen-rich extracellular matrix, show potential in DFU therapy. Multicentre RCTs have demonstrated significant improvements in DFU healing compared to standard of care [70,71].

Vancomycin and imipenem/cilastatin-loaded nanofibres have shown promise in inhibiting bacterial growth, with the potential for delivering crucial medications for DFU treatment [72].

Electrical stimulation has emerged as an economical, safe, and effective adjunctive therapy for DFU healing, addressing common deficiencies such as poor cellular responses, inadequate blood circulation, and infection [44].

Acknowledgement

The authors would like to thank the faculties of the Department of Microbiology (IIMS&R), Integral University (MCN: IU/R&D/2024-MCN0002449) for their guidance and support in completing their research work.

CONCLUSION(S)

The take-home message from the present review is that DFUs are a serious complication of diabetes that can lead to lower limb amputation if not addressed with a timely, evidence-based, multidisciplinary approach. The key elements of an effective DFU management plan, crucial for expediting and ensuring successful wound healing, include patient education, glycaemic control, wound debridement, advanced wound dressings, offloading pressure on the foot, surgical interventions, and the use of cutting-edge therapies. Consistently implementing these strategies is essential in reducing the significant burden of morbidity associated with DFUs and preventing the potentially life-threatening consequences of this condition. The overarching message is that a proactive, comprehensive, and multidisciplinary approach is paramount in managing DFUs and preventing the dire outcomes, they can lead to.

REFERENCES

- [1] Dogruel H, Aydemir M, Balci MK. Management of diabetic foot ulcers and the challenging points: An endocrine view. *World J Diabetes*. 2022;13(1):27-36.
- [2] Khan MM, Sonkar GK, Alam R, Mehrotra S, Khan MS, Kumar A, et al. Validity of Indian Diabetes Risk Score and its association with body mass index and glycosylated hemoglobin for screening of diabetes in and around areas of Lucknow. *J Family Med Prim Care*. 2017;6:366-73.
- [3] Saluja S, Anderson SG, Hambleton I, Shoo H, Livingston M, Jude EB, et al. Foot ulceration and its association with mortality in diabetes mellitus: A meta-analysis. *Diabet Med*. 2020;37:211-18.
- [4] Pandey S, Shaif M, Ansari TM, Shamim A, Kushwaha P. Leveraging potential of nanotherapeutics in management of diabetic foot ulcer. *Exp Clin Endocrinol Diabetes*. 2022;130(10):678-686. Doi: 10.1055/a-1749-4909. Epub 2022 Mar 3. PMID: 35240693.
- [5] Syafri S. Pathophysiology diabetic foot ulcer IOP Conf. Ser: Earth Environ Sci. 2018;125:012161.
- [6] Oliver TI, Mutluoglu M. Diabetic Foot Ulcer. In: StatPearls. Treasure Island (FL): StatPearls Publishing; 2022. PMID: 30726013.
- [7] Baig MS, Banu A, Zehravi M, Rana R, Burle SS, Khan SL, et al. An overview of diabetic foot ulcers and associated problems with special emphasis on treatments with antimicrobials. *Life*. 2022;12:1054.
- [8] Ruke MG, Savai J. Diabetic foot infection, biofilm & new management strategy. *Diabetes Res Open Access*. 2019;1:07-22.
- [9] Sun H, Saeedi P, Karuranga S, Pinkepank M, Ogurtsova K, Duncan BB, et al. IDF Diabetes Atlas: Global, regional and country-level diabetes prevalence estimates for 2021 and projections for 2045. *Diabetes Res Clin Pract*. 2022;183:109119.
- [10] Boulton AJM, Armstrong DG, Londahl M, Frykberg RG, Game FL, Edmonds ME, et al. New evidence-based therapies for complex diabetic foot wounds. Arlington (VA): American Diabetes Association; 2022. PMID: 35763580.
- [11] Syed MH, Salata K, Hussain MA, Zamzam A, de Mestral C, Wheatcroft M, et al. The economic burden of inpatient diabetic foot ulcers in Toronto, Canada. *Vascular*. 2020;28(5):520-29. Doi: 10.1177/1708538120923420.

- [12] Deng P, Shi H, Pan X, Liang H, Wang S, Wu J, et al. Worldwide research trends on diabetic foot ulcers (2004-2020): Suggestions for researchers. *J Diabetes Res.* 2022;2022:7991031.
- [13] American Diabetes Association. Microvascular complications and foot care: Standards of medical care in diabetes-2021. *Diabetes Care.* 2021;44(Suppl 1):S151-S167.
- [14] Hinchliffe RJ, Forsythe RO, Apelqvist J, Boyko EJ, Fitridge R, Hong JP, et al; International Working Group on the Diabetic Foot (IWGDF). Guidelines on diagnosis, prognosis, and management of peripheral artery disease in patients with foot ulcers and diabetes (IWGDF 2019 update). *Diabetes Metab Res Rev.* 2020;36(Suppl 1):e3276.
- [15] Cychosz CC, Phisitkul P, Belatti DA, Wukich DK. Preventive and therapeutic strategies for diabetic foot ulcers. *Foot Ankle Int.* 2016;37:334-43.
- [16] Reardon R, Simring D, Kim B, Mortensen J, Williams D, Leslie A. The diabetic foot ulcer. *Aust J Gen Pract.* 2020;49:250-55.
- [17] Alsanawi Y, Alismail H, Alabd Rabalnabi M, Alturki H, Alsuhailani A, Mahbub M. Pathogenesis and management of diabetic foot ulcers. *Int J Community Med Public Health.* 2018;5:4953.
- [18] Muhammad Ibrahim A. Diabetic foot ulcer: Synopsis of the epidemiology and pathophysiology. *Int J Diabetes Endocrinol.* 2018;3:23. Doi: 10.11648/j.ijde.20180302.11.
- [19] Nelson A, Wright-Hughes A, Backhouse MR, Lipsky BA, Nixon J, Bhogal MS, et al. CODIFI (Concordance in Diabetic Foot Ulcer Infection): A cross-sectional study of wound swab versus tissue sampling in infected diabetic foot ulcers in England. *BMJ Open.* 2018;8:e019437.
- [20] Jouhar L, Jaafar RF, Nasreddine R, Itani O, Haddad F, Rizk N, et al. Microbiological profile and antimicrobial resistance among diabetic foot Infections in Lebanon. *Int Wound J.* 2020;17:1764-73.
- [21] Jneid J, Cassir N, Schuldiner S, Jourdan N, Sotto A, Lavigne JP, et al. Exploring the microbiota of diabetic foot infections with culturomics. *Front Cell Infect Microbiol.* 2018;8:282.
- [22] Pereira SG, Moura J, Carvalho E, Empadinhas N. Microbiota of chronic diabetic wounds: Ecology, impact, and potential for innovative treatment strategies. *Front Microbiol.* 2017;8:1791.
- [23] Atlaw A, Kebede HB, Abdela AA, Woldeamanuel Y. Bacterial isolates from diabetic foot ulcers and their antimicrobial resistance profile from selected hospitals in Addis Ababa, Ethiopia. *Front Endocrinol (Lausanne).* 2022;13:987487.
- [24] Banu A, Noorul Hassan MM, Rajkumar J, Srinivasa S. Spectrum of bacteria associated with diabetic foot ulcer and biofilm formation: A prospective study. *Australas Med J.* 2015;8(9):280-85.
- [25] Kadhim FH, Mohammed SH. Microbiological profile, antibiogram, and risk factors of patients with diabetic foot infections: A systematic meta-analysis. *Biomed Biotechnol Res J.* 2021;5:235-44.
- [26] Singh AK, Yeola M, Singh N, Damke S. A study on diabetic foot ulcers in central rural India to formulate empiric antimicrobial therapy. *J Family Med Prim Care.* 2020;9:4216-22.
- [27] Singh S, Banerjee G, Agarwal J, Kumar V, Usman K. Spectrum of microbiota in diabetic foot infections in a teaching hospital of Uttar Pradesh. *Int J Med Sci Public Health.* 2018;7(9):741-47.
- [28] Al-Mijalli SHS. Spectral and antibiotic susceptibility of pathogens isolated from Saudi patients with diabetic foot infections. *Microbiol Res.* 2021;12:16-20.
- [29] Mamdoh H, Hassanein KM, Eltoony LF, Khalifa WA, Hamed E, Alshammari TO, et al. Clinical and bacteriological analyses of biofilm-forming staphylococci isolated from diabetic foot ulcers. *Infect Drug Resist.* 2023;16:1737-50.
- [30] Francisco RB, Vieira CD, Farias L de M, Souza AE de, Castro BL de, Braga RRR, et al. Microbial content recovered from diabetic foot infections: A cross-sectional study in Brazil/Conteúdo microbiano recuperado em infecções de pé diabético: Um estudo transversal no Brasil. *Braz J Develop.* 2020;6(10):76209-22.
- [31] Rai S, Uppal H, Sharma AK, Gupta AK. Clinical and microbiological profile of diabetic foot ulcers in a tertiary care setup: A cross-sectional analysis. *Int J Adv Med.* 2021;8:897-901.
- [32] Aleem S, Multani H, Bashir H. Bacteriological profile and antimicrobial sensitivity pattern of isolates from the diabetic foot of patients attending a teaching hospital in Northern India. *Asian J Med Sci.* 2021;12(5):83-87.
- [33] Shah P, Eswarawaka M, Anne D, Reddy SCM, Shah P, Srivastava N. Bacteriological profile of diabetic foot. *Int Surg J.* 2021;8:704-09.
- [34] Kumar A, Agrawal AK, Kumar M, Sharma AK, Kumari P. Aerobic bacterial profile of diabetic foot and its antibiogram in RIMS, Ranchi-a tertiary care hospital. *Int J Contemp Med Res.* 2017;4(1):251-53.
- [35] Jain SK, Barman R. Bacteriological profile of diabetic foot ulcer with special reference to drug-resistant strains in a tertiary care centre in North-East India. *Indian J Endocr Metab.* 2017;21:688-94.
- [36] CLSI Performance Standards for Antimicrobial Susceptibility Testing. 29th ed. CLSI supplement M100. Wayne, PA: Clinical and Laboratory Standards Institute; 2019.
- [37] Kathirvel M, Prabakaran V, Jayarajan J, Sivakumar A, Govindan VR. Risk factors for diabetic foot infection with multidrug-resistant microorganisms in South India. *Int Surg J.* 2018;5:675-82.
- [38] Datta P, Chander J, Gupta V, Mohi GK, Attri AK. Evaluation of various risk factors associated with multidrug-resistant organisms isolated from diabetic foot ulcer patients. *J Lab Physicians.* 2019;11(1):58-62.
- [39] Liu X, Ren Q, Zhai Y, Kong Y, Chen D, Chang B. Risk factors for multidrug-resistant organisms infection in diabetic foot ulcer. *Infect Drug Resist.* 2022;15:1627-35.
- [40] Karmaker M, Sanyal SK, Sultana M, Hossain MA. Association of bacteria in diabetic and non-diabetic foot infection-an investigation in patients from Bangladesh. *J Infect Public Health.* 2016;9:267-77.
- [41] Dai J, Jiang C, Chen H, Chai Y. Assessment of the risk factors of multidrug-resistant organism infection in adults with type 1 or type 2 diabetes and diabetic foot ulcer. *Can J Diabetes.* 2020;44(4):342-49.
- [42] Matta-Gutierrez G, García-Morales E, García-Alvarez Y, Alvaro-Afonso FJ, Molines-Barroso RJ, Lazaro-Martinez JL. The influence of multidrug-resistant bacteria on clinical outcomes of diabetic foot ulcers: A systematic review. *J Clin Med.* 2021;10:1948.
- [43] Ramirez-Acuña JM, Cardenas-Cadena SA, Marquez-Salas PA, Garza-Veloz I, Perez-Favila A, Cid-Baez MA, et al. Diabetic foot ulcers: Current advances in antimicrobial therapies and emerging treatments. *Antibiotics (Basel).* 2019;8(4):193.
- [44] Yazdanpanah L, Nasiri M, Adarvishi S. Literature review on the management of diabetic foot ulcer. *World J Diabetes.* 2015;6(1):37-53.
- [45] Musuza J, Sutherland BL, Kurter S, Balasubramanian P, Bartels CM, Brennan MB. A systematic review of multidisciplinary teams to reduce major amputations for patients with diabetic foot ulcers. *J Vasc Surg.* 2020;71(4):1433-46.e3.
- [46] Lo ZJ, Chandrasekar S, Yong E, Hong Q, Zhang L, Chong LRC, et al. Clinical and economic outcomes of a multidisciplinary team approach in a lower extremity amputation prevention programme for diabetic foot ulcer care in an Asian population: A case-control study. *Int Wound J.* 2022;19(4):765-73.
- [47] Khan Y, Khan MM, Farooqui MR. Diabetic foot ulcers: A review of current management. *Int J Res Med Sci.* 2017;5:4683-89.
- [48] Dhatriya K, Corsino L, Umplierrez GE. Management of Diabetes and Hyperglycemia in Hospitalized Patients. In: Feingold KR, Anawalt B, Blackman MR, et al., editors. *Endotext* [Internet]. South Dartmouth (MA): MDText.com, Inc.; 2000.
- [49] Neville RF, Kayssi A, Buescher T, Stempel MS. The diabetic foot. *Curr Probl Surg.* 2016;53:408-37.
- [50] Tayeb KA, Bateman SD, Hampton S, Malone M, Fletcher J. Managing infection: A holistic approach. *J Wound Care.* 2015;24:20-30.
- [51] Everett E, Mathioudakis N. Update on management of diabetic foot ulcers. *Ann N Y Acad Sci.* 2018;1411:153-65.
- [52] Dreyfus J, Delhougne G, James R, Gayle J, Waycaster C. Clostridial collagenase ointment and medicinal honey utilization for pressure ulcers in US hospitals. *J Med Econ.* 2018;21:390-97.
- [53] Khansa I, Schoenbrunner AR, Kraft CT, Janis JE. Silver in wound care-friend or foe? A comprehensive review. *Plast Reconstr Surg Glob Open.* 2019;7(8):e2390.
- [54] Weller CD, Team V, Sussman G. First-line interactive wound dressing update: A comprehensive review of the evidence. *Front Pharmacol.* 2020;11:155.
- [55] Liu Z, Dumville JC, Hinchliffe RJ, Cullum N, Game F, Stubbs N, et al. Negative pressure wound therapy for treating foot wounds in people with diabetes mellitus. *Cochrane Database Syst Rev.* 2018;10:CD010318.
- [56] Cole W, Coe S. Offloading diabetic foot ulcers with the next generation of pressure relief. *Today's Wound Clinic.* 2020.
- [57] Gupta A, Channaveera C, Sethi S, Ranga S, Anand V. Efficacy of intralesional platelet-rich plasma in diabetic foot ulcer. *J Am Podiatr Med Assoc.* 2021;111(3):07.
- [58] Lipsky BA, Senneville E, Abbas ZG, Aragon-Sanchez J, Diggle M, Embil JM, et al. Guidelines on the diagnosis and treatment of foot infection in persons with diabetes (IWGDF 2019 update). *Diabetes Metab Res Rev.* 2020;36:e3280.
- [59] Pavlik V, Sojka M, Mazurova M, Velebný V. Dual role of iodine, silver, chlorhexidine and octenidine as antimicrobial and antiprotease agents. *PLoS One.* 2019;14:e0211055.
- [60] Malone M, Johani K, Jensen SO, Gosbell IB, Dickson HG, McLennan S, et al. Effect of cadexomer iodine on the microbial load and diversity of chronic non-healing diabetic foot ulcers complicated by biofilm in vivo. *J Antimicrob Chemother.* 2017;72(7):2093-101.
- [61] Bronze MS. Diabetic foot infections medication. *Medscape.* 2020.
- [62] Maranna H, Lal P, Mishra A, Bains L, Sawant G, Bhatia R, et al. Negative pressure wound therapy in grade 1 and 2 diabetic foot ulcers: A randomized controlled study. *Diabetes Metab Syndr.* 2021;15(1):365-71.
- [63] Wang N, Li SS, Liu YP, Peng YY, Wang PF. Comparison of negative pressure wound therapy and moist wound care in patients with diabetic foot ulcers: A protocol for systematic review and meta-analysis of randomized controlled trials. *Medicine (Baltimore).* 2022;101(31):e29537.
- [64] Finzgar M, Frangez HB, Cankar K, Frangez I. Transcutaneous application of the gaseous CO₂ for improvement of the microvascular function in patients with diabetic foot ulcers. *Microvasc Res.* 2021;133:104100.
- [65] Fang J, Xu J, Zhang Y, Chen H, Ma Z, Huang Z, et al. Stromal cell-derived factor-1 may play a pivotal role in distraction-stimulated neovascularization of diabetic foot ulcers. *Med Hypotheses.* 2021;149:110548.
- [66] Malekpour Alamdari N, Shafiee A, Mirmohseni A, Besharat S. Evaluation of the efficacy of platelet-rich plasma on healing of clean diabetic foot ulcers: A randomized clinical trial in Tehran, Iran. *Diabetes Metab Syndr.* 2021;15(2):621-26.
- [67] Orban YA, Soliman MA, Hegab YH, Alkilany MM. Autologous platelet-rich plasma vs conventional dressing in the management of chronic diabetic foot ulcers. *Wounds.* 2022;33(2):36-42.
- [68] Kartika RW, Alwi I, Suyatna FD, Yunir E, Waspadji S, Immanuel S, et al. The role of VEGF, PDGF and IL-6 on diabetic foot ulcer after platelet rich fibrin + hyaluronic therapy. *Heliyon.* 2021;7(9):e07934.
- [69] He S, Liang C, Yi C, Wu M. Therapeutic effect of continuous diffusion of oxygen therapy combined with traditional moist wound dressing therapy in the treatment of diabetic foot ulcers. *Diabetes Res Clin Pract.* 2021;174:108743.
- [70] Tettelbach W, Cazzell S, Sigal F, Caporusso JM, Agnew PS, Hanft J, et al. A multicentre prospective randomised controlled comparative parallel study of dehydrated human umbilical cord (EpiCord) allograft for the treatment of diabetic foot ulcers. *Int Wound J.* 2019;16:122-30.

[71]

Tettelbach W, Cazzell S, Reyzelman AM, Sigal F, Caporusso JM, Agnew PS. A confirmatory study on the efficacy of dehydrated human amnion/chorion membrane dHACM allograft in the management of diabetic foot ulcers: A prospective, multicentre, randomised, controlled study of 110 patients from 14 wound clinics. *Int Wound J*. 2019;16:19-29.

[72]

Elsadek NE, Nagah A, Ibrahim TM, Chopra H, Ghonaim GA, Emam SE, et al. Electrospun nanofibers revisited: An update on the emerging applications in nanomedicine. *Materials*. 2022;15:1934.

PARTICULARS OF CONTRIBUTORS:

1.

Ph.D. Scholar, Department of Microbiology, Integral Institute of Medical Sciences and Research, Kursi Road, Lucknow, Uttar Pradesh, India.
2.

Professor, Department of Microbiology, Integral Institute of Medical Sciences and Research, Kursi Road, Lucknow, Uttar Pradesh, India.
3.

Professor, Department of Microbiology, Hind Institute of Medical Sciences, Mau, Ataria, Sitapur, Uttar Pradesh, India.
4.

Assistant Professor, Department of Surgery, Integral Institute of Medical Sciences and Research, Kursi Road, Lucknow, Uttar Pradesh, India.
5.

Professor, Department of Community Medicine, Integral Institute of Medical Sciences and Research, Kursi Road, Lucknow, Uttar Pradesh, India.

NAME, ADDRESS, E-MAIL ID OF THE CORRESPONDING AUTHOR:

Mohd Shahid Khan,
Ph.D. Scholar, Department of Microbiology, Integral Institute of Medical Sciences and Research, Kursi Road, Lucknow-226026, Uttar Pradesh, India.
E-mail: shahid89research@gmail.com

PLAGIARISM CHECKING METHODS: [\[Jain H et al.\]](#)

- Plagiarism X-checker: Aug 04, 2023
- Manual Googling: Oct 13, 2023
- iTenticate Software: Dec 14, 2023 (20%)

ETYMOLOGY: Author Origin

EMENDATIONS: 7

AUTHOR DECLARATION:

- Financial or Other Competing Interests: None
- Was informed consent obtained from the subjects involved in the study? NA
- For any images presented appropriate consent has been obtained from the subjects. NA

Date of Submission: [Aug 04, 2023](#)

Date of Peer Review: [Sep 20, 2023](#)

Date of Acceptance: [Dec 16, 2023](#)

Date of Publishing: [Mar 01, 2024](#)