

Sonographic Assessment of the Thymus and the Measurement of the Thymic Size in Healthy Neonates from North India

RAJIV AZAD, SARITA MAGU, GEETA GATHWALA

ABSTRACT

Objective: To create the reference standards for the thymic size by sonography in healthy neonates in the north Indian population and to assess the variation in its location, echogenicity and echopattern.

Material and Methods: This study was done prospectively on 200 healthy term neonates from north India at less than one week of age. The size of the thymus was measured in terms of the transverse diameter, the sagittal area, the thymic index and the anteroposterior (AP) diameter and the normal reference standards were created. The thymus was assessed in terms of its location, echogenicity (done in terms of the relative echogenicity number) and echopattern. The comparison of the thymic echogenicity and the echopattern with that of the liver, spleen and the thyroid was also performed.

Results: The range of the thymic transverse diameter was 1.6-4.2 cm (mean 2.68 ± 0.54), that of the sagittal area was 1.31-5.13 cm² (mean 3.01 ± 0.74), that of the thymic index was 2.60-16.93 cm³ (mean 8.10 ± 2.74), that of the AP (Right) was 0.50-2.30 cm (mean 1.27 ± 0.35), that of the AP (left) was 0.20-2.90 cm (mean 1.72 ± 0.4) and that of the AP (mean) was 0.40-2.35 cm (mean 1.49 ± 0.33). The thymus was located in the supero-anterior mediastinum and it was less echogenic than the liver, spleen and the thyroid. In majority of the subjects, the thymus was coarser in echo pattern than the spleen. However, it resembled or was coarser than the liver and the thyroid in almost equal proportions.

Conclusion: The normative standards of the thymic size and the thymic appearance in a given population are useful in assessing this complex lymphoid organ sonographically in health and disease and also to carry out various immunological studies.

Key Words: Thymus, neonates, sonography

INTRODUCTION

The thymus is a complex, lymphoid organ that plays an important role in the immune system by providing the environment for T-cell differentiation and maturation [1]. In order to detect the pathological conditions which are related to the size of the thymus or to conduct comparative immunological studies, it is important to know the normal range of the size of the thymus [2]. The measurement of the thymic size may be a useful non-invasive indicator of the overall immunological status of the child [3]. In neonates, infants and young children, sonography has its inherent advantages and thus, in recent years, reference standards for the thymic size and the thymic appearance for this age group have been established in various studies by sonography [2-11].

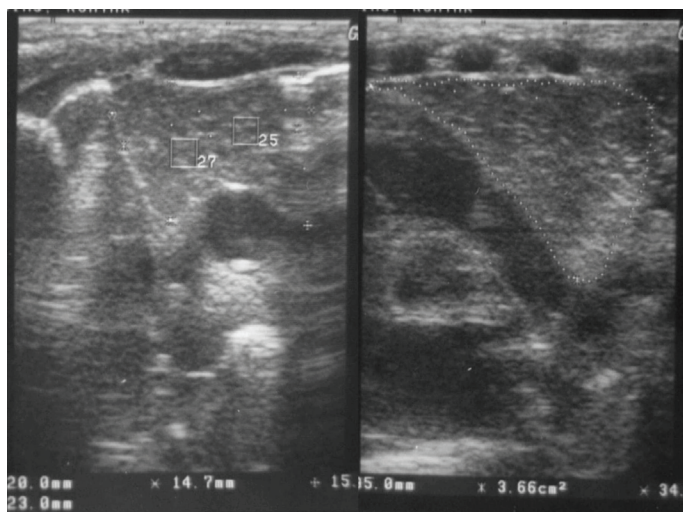
The present study was undertaken to evaluate the normal thymic dimensions in neonates in the north Indian population.

MATERIAL AND METHODS

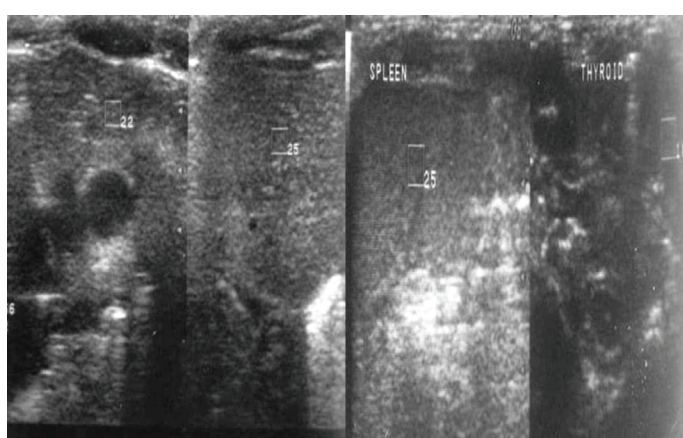
This study comprised 200 healthy neonates who were born at term (gestational age 37 to 42 weeks). Parental informed consent was taken for the study. The gestational age of these neonates was assessed by the mother's dates and were confirmed clinically by using Ballard's criteria [12]. The criteria with regards to the selection of the study population were the normal duration of labour, no use of instrumentation (forceps or vacuum), no antenatal complications (like maternal eclampsia, heart disease or diabetes) and no history of maternal drug intake. Neonates with a history of foetal distress, perinatal asphyxia and drug intake were also excluded from the study.

Linear, 5-10 MHz wide frequency transducers were used to evaluate the thymus on a real time scanner (Logiq 400 and 500 MD, GE Healthcare, USA). The thymus was visualized by the trans-sternal, supra-sternal and the para-sternal approaches. A trans-sternal approach was used to measure the maximum transverse diameter (width) of the thymus and perpendicular to that, the largest sagittal area was measured in the longitudinal scan plane [Table/Fig-1A, B]. The transverse diameter and the sagittal area were then multiplied and registered as the thymic index. The average of the two determinations was used as the result. The thymic index is then accepted as an estimate of the volume of the thymus [4]. The maximum antero-posterior (AP) diameters on the right and left sides were recorded. The average of these two diameters was taken as the mean anteroposterior (AP) diameter. The distribution of the transverse diameter, the sagittal area, the mean AP diameter and the thymic index according to various clinical variables like weight, length, period of gestation (POG) and sex were also analyzed. A single radiologist performed all the measurements in order to remove interobserver variations. The Microsoft Office Excel 2007 software was used for various calculations.

Appearance of the thymus: The thymic appearance was described in terms of its echogenicity and echopattern, which were compared with that of the liver, spleen and the thyroid without changing the overall gain settings. Its echogenicity was measured quantitatively by the measurement of the echogenicity number facility which was available in our machine. No significance was attached to the absolute value of the echonumber, but the difference of the echonumber at the same gain settings between other



[Table/Fig-1A&B]: Transverse sonogram (A) and longitudinal sonogram (B) of the thymus for measurement of various thymic dimensions.



[Table/Fig-2A&B]: Sonographic comparison of echogenicity and echopattern of thymus with liver, spleen and thyroid with measurement of relative echonumber of thymus, liver, spleen and thyroid at same gain settings.

organs (liver, spleen and thyroid) and the thymus was termed as the relative echonumber [Table/ Fig 2 A, B] and it was used to devise an arbitrary grading system for the purpose of the comparison of the echogenicity of the thymus, as described below. The grading was done from the - 4 to + 4 grades, keeping the echogenicity number of the thymus as the reference value, with the positive grades denoting echogenicity more than the thymus and the negative grades denoting echogenicity less than the thymus.

Grading System denoting the relative echonumber (echonumber difference) between the other organs (liver, spleen and thyroid) and the thymus.

Grade	Relative echonumber
-4	≤ -10
-3	-9 to -7
-2	-6 to -4
-1	-3 to -1
0	0
1	1 to 3
2	4 to 6
3	7 to 9
4	≥ 10

When the echoes are stacked together in a small space, the echopattern is fine and when the echoes are widely distributed in space, the pattern is coarse.

RESULTS

The thymus was uniformly located in the superoanterior mediastinum. Only in one case, it extended to the cervical area.

There were 123 male and 77 female neonates, with a median weight of 2.87 Kg (range 2.0-3.9 Kg) and a median length of 47 cm. (range 40- 52 cm)

The range of the thymic transverse diameter was 1.6-4.2 cm (mean 2.68 ± 0.54), that of the sagittal area was 1.31–5.13 cm² (mean 3.01 ± 0.74), that of the thymic index was 2.60–16.93 cm³ (mean 8.102.74), that of the AP (Right) was 0.50–2.30 cm (mean 1.27 ± 0.35), that of the AP (left) was 0.20–2.90 cm (mean 1.72 ± 0.4) and that of the AP (mean) was 0.40–2.35 cm (mean 1.49 ± 0.33).

The results are presented in [Tables/Figs-3-5], which show the distribution of the transverse diameter, the sagittal area, the thymic index and the AP diameter (mean) according to the weight, length, period of gestation (POG) and sex separately.

	Transverse Diameter (cm)	Sagittal area (cm ²)	Thymic index (cm ³)	AP(mean) Diameter (cm)
	Range (Mean)	Range (Mean)	Range (Mean)	Range (Mean)
37+	1.80-3.90 (2.63)	1.69-4.14 (2.91)	3.38-13.86 (7.72)	0.65-2.05 (1.45)
38+	1.70-4.20 (2.57)	1.70-4.54 (2.89)	3.33-16.09 (7.52)	0.40-2.30 (1.44)
39+	1.80-3.90 (2.62)	1.31-5.13 (3.18)	2.60-16.93 (8.36)	0.90-2.20 (1.46)
40+	1.90-3.80 (2.78)	1.58-4.65 (3.14)	3.16-16.19 (8.79)	0.70-2.35 (1.59)
41+	1.60-3.80 (2.81)	1.50-4.04 (2.87)	2.85-14.54 (8.14)	0.85-2.15 (1.54)

[Table/ Fig-3]: Distribution of the thymic dimensions according to the Period of Gestation (POG) of the neonates.

	Transverse Diameter (cm)	Sagittal area (cm ²)	Thymic index (cm ³)	AP(mean) Diameter (cm)
	Range (Mean)	Range (Mean)	Range (Mean)	Range (Mean)
Boy	1.80-4.20 (2.68)	1.31-5.13 (3.04)	2.60-16.93 (8.21)	0.40-2.30 (1.50)
Girl	1.60-3.90 (2.67)	1.58-4.54 (2.96)	3.16-13.97 (7.93)	0.65-2.35 (1.48)

[Table/Fig 4]: Distribution of the thymic dimensions according to the sex of the neonates

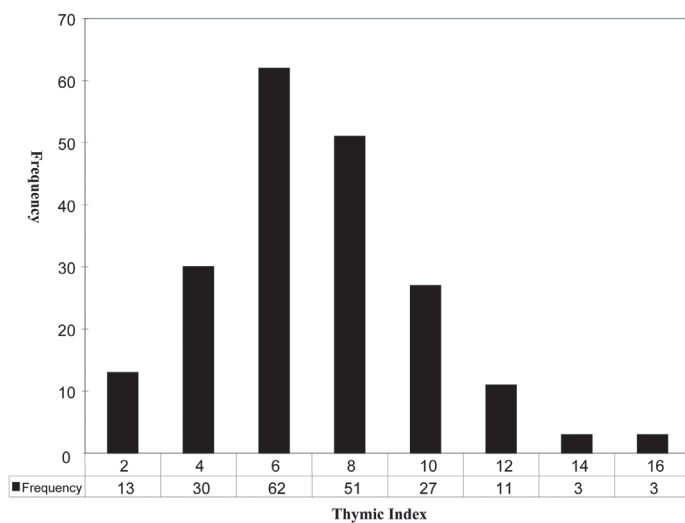
Distribution of the thymic index in the study group is separately shown as a histogram [Table/ Fig 6].

Echogenicity: In 192 subjects out of the 200 (96 %), the thymic echogenicity was less than the echogenicity of the liver. The mean value of the echogenicity number difference between the liver and the thymus was 6.47. In 174 subjects out of the 200 (87%), the thymus was less echogenic than the spleen. The mean value of the echogenicity number difference between the spleen and the thymus was 5.27. In 128 subjects out of the 200 (64%), the thymic echogenicity was less than the echogenicity of the thyroid. The mean value of the echogenicity number difference between the thyroid and the thymus was 2.3.

The Histogram [Table/ Fig 7] shows the difference in the grades of echogenicity between other organs (liver, spleen and the thyroid) and the thymus. The median grading difference was grade 3

Parameter		Transverse diameter (cm)	Sagittal Area (cm ²)	Thymic index (cm ³)	AP (mean) Diameter (cm)
		Range (Mean)	Range (Mean)	Range (Mean)	Range (Mean)
Weight (Kg)	2.0-2.5	1.70-3.50 (2.35)	1.31-3.90 (2.45)	2.75-12.50 (5.85)	0.65-2.05 (1.41)
	2.5-3.0	1.60-3.90 (2.61)	1.74-4.55 (2.96)	3.33-13.97 (7.72)	0.40-2.35 (1.44)
	3.0-3.5	1.90-4.20 (2.9)	1.37-4.86 (3.28)	2.60-16.19 (9.52)	0.95-2.15 (1.57)
	3.5-4.0	2.00-3.60 (2.83)	2.60-5.13 (3.65)	7.40-16.93 (10.43)	1.25-2.20 (1.71)
Length (cm)	40-42	1.70-3.30 (2.32)	1.31-3.99 (2.47)	2.75-9.37 (5.81)	0.65-2.05 (1.31)
	42-44	1.90-3.90 (2.75)	1.95-4.54 (3.06)	4.10-13.17 (8.38)	0.80-1.95 (1.36)
	44-46	1.80-3.80 (2.57)	1.58-4.34 (3.06)	3.16-12.77 (7.91)	0.40-1.9 (1.42)
	46-48	1.80-3.90 (2.59)	1.70-4.71 (2.95)	3.33-13.36 (7.65)	0.70-2.05 (1.48)
	48-50	1.60-3.70 (2.79)	1.74-5.13 (3.02)	3.44-16.93 (8.44)	0.85-2.35 (1.61)
	50-52	1.90-4.20 (2.95)	1.37-4.86 (3.27)	2.60-16.19 (9.68)	0.95-2.15 (1.56)
	52-54	2.00-3.10 (2.62)	2.15-3.84 (3.40)	6.24-10.85 (8.8)	1.45-1.90 (1.66)

[Table/ Fig 5]: Distribution of the thymic dimensions according to the anthropometric parameters (weight and length) of the neonates



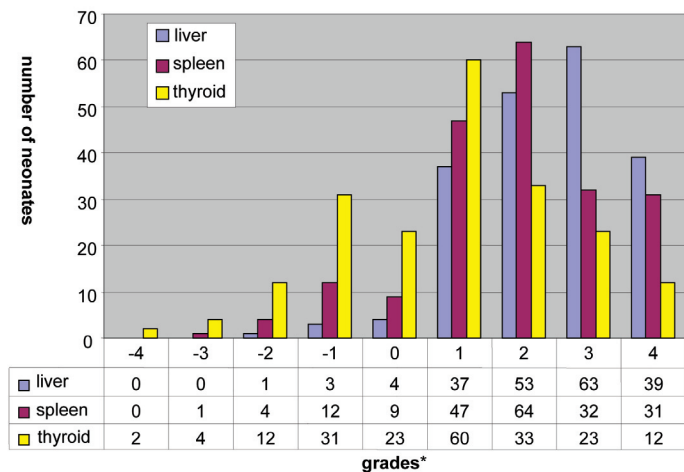
[Table/Fig-6]: Histogram showing distribution of the thymic index in healthy neonates in North Indian population

between the liver and the thymus, grade 2 between the spleen and the thymus and grade 1 between the thyroid and the thymus.

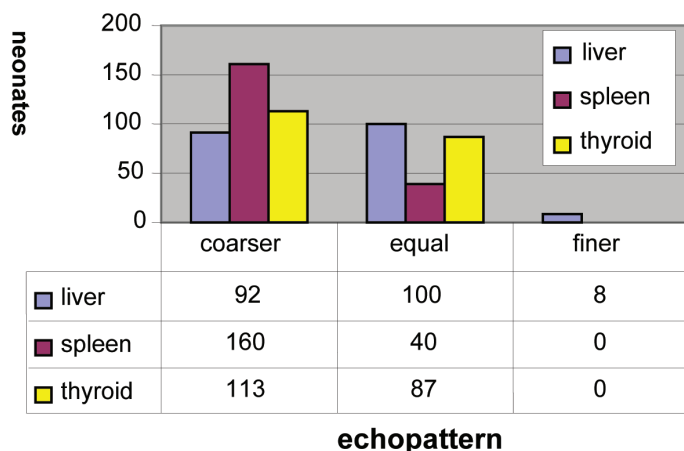
Echopattern: The echopattern of the thymus was compared to that of the liver, spleen and the thyroid. The Histogram [Table/Fig 8] shows the comparison in terms of coarse, equal and fine. In a majority of the subjects, the thymus was coarser in echopattern than the spleen and it resembled or was coarser than the liver and the thyroid in almost equal proportions.

DISCUSSION

The present study provides the normative standards of the thymic dimensions and the appearance of the thymus in healthy neonates in our population by using sonography, which is a readily available, cheap, radiation free and easy to use modality in neonates. These



[Table/Fig-7]: Histogram showing the difference in grades of echogenicity between other organs (liver, spleen and thyroid) and thymus



[Table/Fig-8]: Histogram showing the comparison of echopattern of thymus with liver, spleen and thyroid

standards can be of immense use in assessing the thymic size and the appearance of the thymus in neonates who are suspected to be suffering from congenital or acquired diseases and disorders of the thymus. In addition, the sonographic assessment of the thymic size may be useful in assessing the immune development of infants and a change in size may be seen with various nutritional and environmental determinants [1-3].

Since the thymic size is known to be effected by stress, only healthy neonates who were delivered by the vaginal route were included in this study by applying carefully selected exclusion criteria, as has been described earlier.

The anthropometric parameters [Table/ Fig 5] in our population were lower than that which were reported by other studies, mainly from the western world, because of the smaller body habitus of the Indian neonates and the Indian population in general [4-8].

A few sonographic studies which have established the normative data of the thymus have been published in the literature, however; to the best of our knowledge, this is the first such study from the Indian population [2-11].

In our study, the mean transverse and the AP diameters and the thymic index were approximately 10-20 % lower than that which were recorded by other studies [5-9]. The overall thymic dimensions and the thymic index in particular, in the Indian neonates, are lower, probably because of the lower birth weight, which correlated significantly with the thymic index (R²=0.29, P<0.001) in our study. In addition to the birth weight, other factors like racial, socio-

economical, geographical and nutritional ones could also play a significant role.

Like in few of the previous studies, no significant difference in the thymic dimensions was seen between the boys and girls in this study, although Liang et al found the thymic width and thickness to be different in boys and girls [5-7].

In addition to the size, the normal thymic appearance may also change due to various pathological, immunological or environmental factors. Since the thymus is not a routinely evaluated organ, it is better to use objective differences in the appearance, in comparison to different organs, to pick up even the subtle variations. In addition, by using these parameters, intra and interobserver variations could be drastically reduced. We have given the objective normative values and grades of the relative echo number in the study population, unlike the previous studies which were more subjective [6, 10].

We compared the echopattern of the thymus with the liver, the spleen and the thyroid. We found that the thymic echopattern either resembled or was coarser than the liver and thyroid, while it was coarser than the spleen in most of the neonates. Earlier studies have found the thymus to resemble the liver and the splenic echopattern and to be coarser than the thyroid in most of their subjects [6, 7, 9-11].

Further studies in a larger study group are required to extrapolate the results in the overall population. However, a single radiologist carrying out all the measurements at least two times did reduce interobserver and statistical variations.

After attempting to create the reference standards of the thymic dimensions and the thymic appearance in Indian neonates, we then tried to find the correlation of these parameters with the various environmental, immunological and clinical variables, which forms the basis of another study.

CONCLUSION

Sonography, with its inherent advantages, is a very useful modality in assessing the thymus in neonates. The normative standards

for assessing the thymic dimensions and the thymic appearance which this study provides, are a must to evaluate the changes of the thymic dimensions in health and congenital states, as well as in the acquired diseases of the thymus. The thymic dimensions may also be noninvasive indicators for the immunological status in infancy.

REFERENCES

- [1] Roitt I. The thymus. *In*: Roitt I, Editor. Essential Immunology, 7th ed. London, Blackwell Scientific Publishers, 1991;173-5.
- [2] Hasselbalch H, Jeppesen DL, Ersboll AK, Engelmann MD, Nielsen MB. The thymus size as evaluated by sonography. A longitudinal study on infants during the first year of their life. *Acta Radiol* 1997;38:222-27.
- [3] Moore SE, Prentice AM, Wagatsuma Y, Fulford AJ, Collinson AC, Raqib R, et al. Early- life nutritional and environmental determinants of thymic size in infants born in rural Bangladesh. *Acta Paediatr* 2009;98:1168-75.
- [4] Hasselbalch H, Nielsen MB, Jeppesen D, Pedersen JF, Karkov J. Sonographic measurements of the thymus in infants. *Eur J Radiol* 1996;6:700-03.
- [5] Hasselbalch H, Jeppesen DL, Ersboll AK, Lisse IM, Nielsen MB. Sonographic measurement of the thymic size in healthy neonates. Its correlation with clinical variables. *Acta Radiol* 1997;38:95-98.
- [6] Yekeler E, Tambag A, Tunaci A, Gencellac H, Dursun M, Gokcay G, et al. Analysis of the thymus in 151 healthy infants from 0 to 2 years of age. *J Ultrasound Med* 2004;23:1321-26.
- [7] Liang CD, Huang SC. Sonographic study of the thymus in infants and children. *J Formos Med Assoc* 1997;96:700-3.
- [8] Varga I, Toth F, Uhrinova A, Nescakova E, Polak S. The association between the size of the thymus, its anthropometric dimensions and the number of lymphocytes in the peripheral blood in newborns from Slovakia. *Biomed Pap Med Fac Univ Palacky Olomouc Czech Repub* 2009;153:229-34.
- [9] Adam EJ, Ignotus PI. Sonography of the thymus in healthy children: Frequency of the visualisation, size and appearance. *Am J Roentgenol* 1993;161:153-55.
- [10] Han BK, Babcock DS, Oestreich AE. Normal thymus in infancy: Sonographic characteristics. *Radiology* 1989;170:471-74.
- [11] Lemaitre L, Marconi V, Avni F, Remy J. The sonographic evaluation of the normal thymus in infants and children. *Eur J Radiol* 1987;7:130-36.
- [12] Ballard JL, Novak KK, Driver M. A simplified score for the assessment of the fetal maturation of newly born infants. *J Pediatr* 1979;95:769-74.

AUTHOR(S):

1. Dr. Rajiv Azad
2. Dr. Sarita Magu
3. Dr. Geeta Gathwala

PARTICULARS OF CONTRIBUTORS:

1. M.D., Associate Professor,
Department of Radiology,
SGRR Institute of Medical & Health Sciences,
Patel Nagar, Dehradun, India.
Formerly Lecturer, Department of Radiology,
Pt BDS, PGIMS, Rohtak, Haryana, India.
2. M.D., Professor,
Department of Radiology,
Pt BDS, PGIMS, Rohtak, Haryana, India.
3. MBBS, M.D., D.M., Professor,
Department of Paediatrics,
Pt BDS, PGIMS, Rohtak, Haryana, India.

NAME, ADDRESS, TELEPHONE, E-MAIL ID OF THE CORRESPONDING AUTHOR:

Dr. Rajiv Azad,
Associate Professor, Department of Radiology,
SGRR Institute of Medical & Health Sciences,
Patel Nagar, Dehradun, India- 248001.
Phone- 911352522131
E-mail: rajivas23@yahoo.com

DECLARATION ON COMPETING INTERESTS:

No competing Interests.

Date of Submission: **May 11, 2011**
Date of peer review: **Aug 02, 2011**
Date of acceptance: **Aug 03, 2011**
Date of Publishing: **Nov 30, 2011**