

# Rigid Bronchoscopy and Jet Ventilation in Foreign Body Aspiration in A Two-Year-Old Female: A Case Report

TRIDIP JYOTI BORAH<sup>1</sup>, JAIDEEP SONOWAL<sup>2</sup>, LT SAILO<sup>3</sup>, SAURAV NANDY<sup>4</sup>

## ABSTRACT

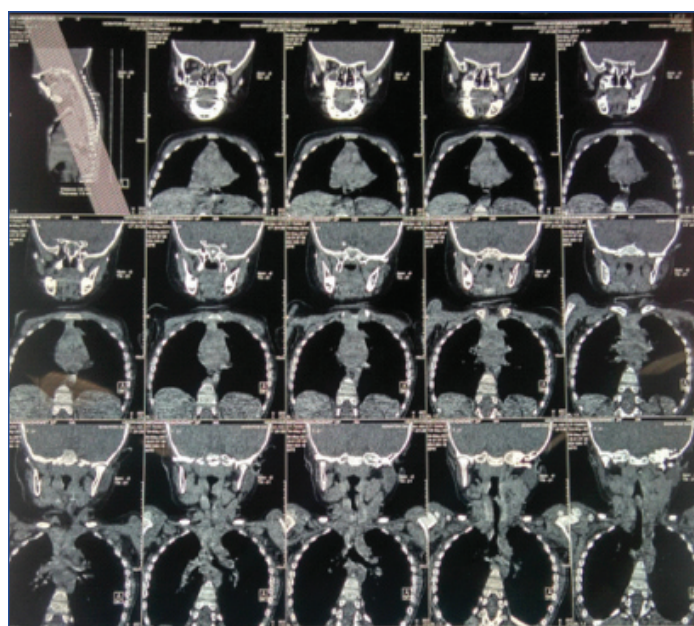
Foreign body aspiration is a leading cause of mortality in children of age group 1-3 years and presents significant challenges to the anaesthesiologist in maintaining oxygenation and ventilation while there is instrumentation of the airway by the endoscopist. Here, we report a two-year-old child who came to the emergency room with sudden onset breathlessness, coughing and bluish discoloration. The foreign body lodged in the right mainstem bronchus was removed with the help of a rigid bronchoscope and oxygenation was maintained with jet ventilation. The cooperation between the anaesthesiologist and the endoscopist, proper timing of the procedure, choice of anaesthetic technique and familiarity with equipments saved the child.

**Keywords:** Breathlessness, Halothane, Manujet III, Premedication

## CASE REPORT

A two-year-old female child, weighing 10 kg was admitted in emergency room with sudden onset breathlessness, coughing and bluish discoloration. The mother informed the doctor on duty that she last saw the child playing with a small beaded necklace at home the previous evening. On examination, there was fever (101°F), cyanosis, respiratory distress, diminished chest movements, decreased breath sounds and wheezing on the right side. The heart rate was 170 beats/min, blood pressure 110/60 mm of Hg and O<sub>2</sub> saturation (SpO<sub>2</sub>) of 80% with O<sub>2</sub> via face mask. High Resolution Computed Tomography (HRCT) of the chest revealed foreign body lodged in the right mainstem bronchus [Table/Fig-1].

Urgent rigid bronchoscopy was planned as conservative management with Inj. hydrocortisone 20 mg IV stat followed by 10 mg IV OD in divided doses and nebulisation with salbutamol 8 hourly, which did not improve the respiratory distress and cyanosis. Routine monitors and precordial stethoscope were attached.



**[Table/Fig-1]:** HRCT Thorax (coronal section) showing hyperdense lesion (Arrow), probably depicting the foreign body lodged in the right mainstem bronchus.

After securing intravenous access in the right hand, the child was preoxygenated with 100% O<sub>2</sub> for 3 minutes and premedicated with Inj. atropine 200 mcg IV. The child was induced with halothane 3-4% via face mask. For muscle relaxation succinylcholine 15 mg IV was administered and topical lidocaine 10% was sprayed in laryngeal inlet to prevent laryngospasm. Once the child was apnoeic and the saturation reached 100%, the surgeon introduced a 3.5 mm sized bronchoscope. Intermittent positive pressure ventilation was continued through the side port of the bronchoscope with the help of jet ventilation with manujet III. Anaesthesia was maintained with repeat doses of propofol. The manual Intermittent Positive Pressure Ventilation (IPPV) was performed with the frequency of 20-25 breaths/minute and the tidal volume was adequate when the chest of the patient was lifted up moderately. The surgeon was able to confirm the presence of the foreign body in the right mainstem bronchus visually and was able to retrieve the foreign body after couple of attempts. Check bronchoscopy was then done to inspect the impact site for full clearance of foreign body, trauma and bleeding. Inj. dexamethasone 4 mg IV, humidified oxygen and bronchodilators were given prophylactically postoperatively. Nebulized racemic epinephrine was given whenever necessary to prevent postoperative stridor and distress.

In the postoperative care unit, the child showed signs of improvement. There was no respiratory distress and cyanosis had disappeared. Air entry was present bilaterally but slightly less on the right side. The child was taken care of in the postoperative care unit and discharged on the fourth postoperative day.

## DISCUSSION

Foreign-body aspiration in the airway is one of the cause of respiratory problems in children, leading to an increased risk of mortality, and is a prevalent cause of medical emergencies [1-5]. The maximum risk of foreign-body aspiration in the airway of children occurs during the first 3 years of life and often in the 1-3-year age range [6-8]. The most common site for an airway foreign body is the right lower bronchus or its bronchus intermedius as it is more vertical, shorter and wider [9]. Anaesthetic management for removal of tracheobronchial foreign body in children is challenging as the anaesthetists should not only ensure adequate ventilation and oxygenation, but also provide a broad perspective and adequate operating time for the surgeons. In

our case, HRCT not only confirmed the diagnosis but also gave a fair idea about the size and location of the foreign body [10]. Previous studies [11,12] evaluated the effect of rigid bronchoscopy in children using Manujet III manual jet ventilation and confirmed the reduction in the incidence of intraoperative hypoxia along with easier surgical removal of foreign bodies. We also used a rigid bronchoscope to retrieve the foreign body. Rigid bronchoscopy for retrieval of foreign bodies is a fairly common procedure in paediatric age group. Complications include bleeding, laryngeal trauma, laryngeal oedema, laryngospasm, bronchospasm, infection, hypoxemia, tracheobronchial laceration and pneumothorax. In infants and smaller children, the rigid bronchoscope is the instrument of choice as it allows better ventilation and control of the airway [13,14].

Premedication with Inj. atropine helped not only to decrease the airway secretions but also prevented bradycardia response to airway manipulation by the rigid bronchoscope. Halothane was used for induction which is a potent bronchodilator. Muscle relaxation was used for controlled ventilation not only to decrease the anaesthetic requirements but also to prevent coughing, trauma, and easier removal of foreign bodies through the vocal cords [13]. Succinylcholine was used for muscle relaxation which is an ultra-short acting depolarizing muscle relaxant. It has the fastest onset and duration of action amongst all muscle relaxants owing to its degradation by cholinesterase in the body which is independent of hepatic and renal function. This property of faster neuromuscular recovery and the onset of spontaneous breathing before blood oxygen levels fall were vital to the use of jet ventilation in our case. Maintenance was done with propofol having the advantages of fast response, short half-life, obvious bronchiectasis and suitable pharmacokinetic characteristics for anaesthesia of bronchoscopy-assisted surgery [15,16]. We used the Manujet III for jet ventilation at a respiratory rate of 20-30 breaths/minute. In the present case, method of jet ventilation gave  $FiO_2$  of 30% and maximum pressure of 22 cm of  $H_2O$  [17]. Careful intermittent ventilation not only helped the oxygenation but also prevented the dislodging the foreign body further down the bronchus.

## CONCLUSION

The perils of administration of anaesthesia to a child, the complications of lodging of the foreign body in the bronchus and the dangers of the use rigid bronchoscope itself make such a case a challenge to any anaesthesiologist. However, appropriate cooperation between the anaesthesiologist and the endoscopist,

proper timing of the procedure, choice of anaesthetic technique and familiarity with equipments will help them both to come out of this tricky situation.

## REFERENCES

- [1] Foltran F, Ballali S, Rodriguez H, Sebastian van As AB, Passali D, Gulati A, et al. Inhaled foreign bodies in children: a global perspective on their epidemiological, clinical, and preventive aspects. *Pediatric Pulmonol.* 2013;48(4):344-51.
- [2] Vijaykumar TK, Kulkarni NH, Bidri LH. Management of Tracheobronchial Foreign body aspirations in Pediatric age group-A 10 year retrospective analysis. *Indian J Anaesth.* 2007;51(1):20-23.
- [3] National Safety Council, Injury Facts 2015. Available at: <http://www.nsc.org/learn/safety-knowledge/Pages/injury-facts.aspx> (Accessed on November 24, 2015).
- [4] Parida P, Nirmal NS, Gopalakrishnan S, Saxena SK. Factors predicting early diagnosis of pediatric laryngotracheobronchial foreign bodies. *Otolaryngol Pol.* 2015;69(6):31-35.
- [5] Williams A, George C, Atul P, Shukla S, Sam S. An audit of morbidity and mortality associated with foreign body aspiration in children from a tertiary level hospital in Northern India. *Afr J Paediatr Surg.* 2014;11(4):287-92.
- [6] Dikensoy O, Usalan C, Filiz A. Foreign body aspiration: clinical utility of flexible Bronchoscopy. *Postgrad Med J.* 2002;78(921):399-403.
- [7] Sirmali M, Türüt H, Kisacık E, Findik G, Kaya S, Tastede I. The relationship between time of admittance and complications in paediatric tracheobronchial foreign body aspiration. *Acta Chir Belg.* 2005;105(6):631-34.
- [8] Kumbhar S, Ashtekar SD, Kumbhar SK, Ashtekar RS. Tracheo-bronchial tree foreign body aspiration among children: A descriptive study. *International J of Healthcare and Biomedical Research.* 2015;3(3):161-69.
- [9] Limper AH, Prakash UB. Tracheobronchial foreign bodies in adults. *Ann Intern Med.* 1990;112(8):604-09.
- [10] Yang YH, Zhang XG, Zhang JL, Zhang YB, Kou CP. Risk factors for preoperative respiratory complications in children with tracheobronchial foreign bodies. *J Int Med Res.* 2016;44(2):338-45.
- [11] Li S, Liu Y, Tan F, Chen J, Chen L. Efficacy of manual jet ventilation using Manujet III for bronchoscopic airway foreign body removal in children. *Int J Pediatr Otorhinolaryngol.* 2010;74(12):1401-04.
- [12] Tian X, Qiang B, Liu Y, Xia R. Manujet III manual jet ventilation used in tracheobronchial foreign bodies removal in children. *Lin Chung Er Bi Yan Hou Tou Jing Wai Ke Za Zhi.* 2013;27(4):187-88, 192.
- [13] Ehrenwerth Jan, BrullSorin J. Anaesthesia for thoracic diagnostic procedures. In: Kaplan JA, Slinger PD, editors. *Thoracic Anaesthesia.* 3rd ed. Philadelphia: Churchill Livingstone; 2003:174-95.
- [14] Shashidhar K, Rajan RRV, Shah N, Bhat N. Rigid bronchoscopy for foreign body removal: an overview. *Int J Otorhinolaryngol Head Neck Surg.* 2017;3(4):936-38.
- [15] Liu J, Xiao K, Lv X. Anaesthesia and ventilation for removal of airway foreign bodies in 35 infants. *Int J Clin Exp Med.* 2014;7(12):5852-56.
- [16] Swain SK, Mohanty S, Sahu MC, Behera IC. Safe and effective anaesthesia during paediatric rigid bronchoscopy: An experience at a tertiary care centre of Eastern India. *Pediatr Pol.* 2015;90(6):470-73.
- [17] Hartigan PM, Mentzer SJ. Alternative ventilatory techniques practical. *Handbook of Thoracic Anaesthesia: Springer Science+Business Media publisher;* 2012:191-207.

### PARTICULARS OF CONTRIBUTORS:

1. Assistant Professor, Department of Anesthesiology and Critical Care, North Eastern Indira Gandhi Regional Institute of Health and Medical Sciences, Shillong, Meghalaya, India.
2. Senior Resident, Department of Anesthesiology and Critical Care, North Eastern Indira Gandhi Regional Institute of Health and Medical Sciences, Shillong, Meghalaya, India.
3. Assistant Professor, Department of Anesthesiology and Critical Care, North Eastern Indira Gandhi Regional Institute of Health and Medical Sciences, Shillong, Meghalaya, India.
4. Postgraduate Student, Department of Anesthesiology and Critical Care, North Eastern Indira Gandhi Regional Institute of Health and Medical Sciences, Shillong, Meghalaya, India.

### NAME, ADDRESS, E-MAIL ID OF THE CORRESPONDING AUTHOR:

Dr. Tridip Jyoti Borah,  
Room No. D-5, RMO Hostel, North Eastern Indira Gandhi Regional Institute of Health and Medical Sciences,  
Shillong-793018, Meghalaya, India.  
E-mail: tridipborah2@rediffmail.com

Date of Submission: **May 15, 2017**  
Date of Peer Review: **Oct 13, 2017**  
Date of Acceptance: **Mar 05, 2018**  
Date of Publishing: **May 01, 2018**

FINANCIAL OR OTHER COMPETING INTERESTS: None.