

Pyeloduodenal Fistula Complicating Emphysematous Pyelonephritis: Successful Management with Minimally Invasive Approach

PRIYANK YADAV¹, RAJANIKANT R YADAV², SANDEEP NUNIA³, NEELAM SONI⁴, HIRALAL⁵

ABSTRACT

Pyeloduodenal fistulae are rare and usually occur between the right renal pelvis and the duodenum due to their anatomical proximity. Pyeloduodenal fistula occurring due to local extension of emphysematous pyelonephritis has been described as a rare entity. Conservative management is preferred for management of emphysematous pyelonephritis and pyeloduodenal fistulae if renal function is adequate. We describe a case of emphysematous pyelonephritis of the right kidney complicated by a spontaneous pyeloduodenal fistula and perinephric air and urine containing collections managed conservatively with percutaneous nephrostomy and percutaneous drainage of perinephric collections.

Keywords: Conservative management, Percutaneous drainage, Percutaneous nephrostomy

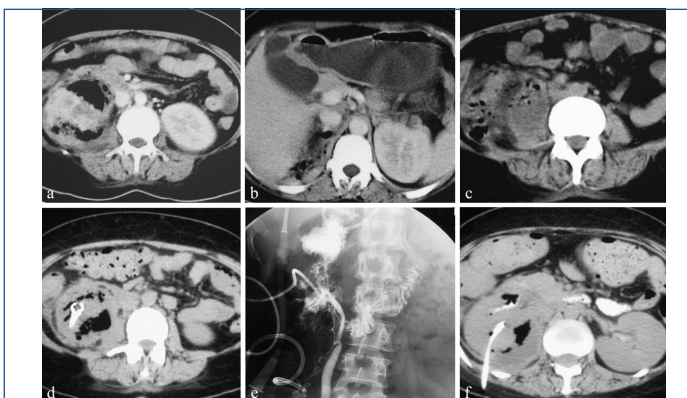
CASE REPORT

A 35-year-old female presented with fever and right flank pain for two weeks. On examination, she was febrile and had a tender lump in the right flank. Her Total Leukocyte Count (TLC) was 16000/ μ L. Differential leukocyte count showed 85% neutrophils and 15% lymphocytes. Serum creatinine was 1.4 mg/dL and random blood glucose was 335 mg/dL. Contrast enhanced Computed Tomography (CT) abdomen showed a heterogeneously enhancing right kidney with parenchymal air collections [Table/Fig-1a] and perinephric air containing suprarenal [Table/Fig-1b] and infrarenal collections with involvement of the right psoas muscle [Table/Fig-1c]. A diagnosis of Emphysematous Pyelonephritis (EPN) type 3B was suggested [1].

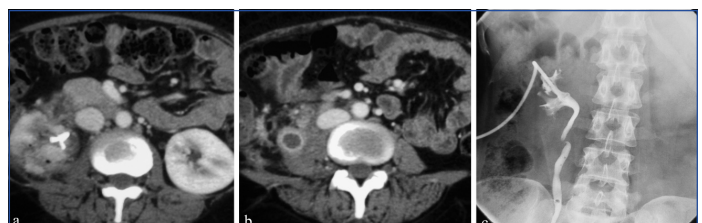The patient was started on insulin and intravenous antibiotics. CT guided Percutaneous Catheters Drainage (PCD, 12 Fr) were placed in a large air containing area in the right kidney [Table/Fig-1d] and in the supra and infra renal fluid collections. The supra and infra renal PCD catheters drained purulent material which on microbiological culture was positive for *Klebsiella pneumoniae*.

After a week of conservative management, the patient's TLC (7900/ μ L) and serum creatinine (1.2 mg/dL) were within normal limits. She was afebrile. As there was no significant drainage from the renal parenchymal PCD catheter, it was removed. However, there was persistent drainage of yellowish fluid from the suprarenal and infrarenal PCD catheters. A retroperitoneal urinary leak was suspected and right sided Percutaneous Nephrostomy (PCN) was done which drained clear urine. Conventional and CT nephrostogram [Table/Fig-1e,f] showed passage of injected contrast into the second part of the duodenum and into the perinephric region. A diagnosis of pyeloduodenal fistula complicating EPN was made. Conservative management was continued.

Contrast CT done after a month showed few small renal parenchymal air foci [Table/Fig-2a] and minimal infrarenal fluid collection [Table/Fig-2d]. Nephrostogram showed no evidence of pyeloduodenal fistula [Table/Fig-2c]. PCD catheters were removed after they had stopped draining. PCN catheter was draining clear urine and removed 48 hours later.



[Table/Fig-1]: Contrast enhanced CT shows heterogeneously enhancing right kidney with parenchymal air containing collection; a) and air containing perinephric fluid collections in the right suprarenal; b) and infrarenal region involving the right psoas muscle; c). Non Contrast CT; d) shows PCD catheter in the right kidney. Post PCN conventional nephrostogram; e) shows passage of contrast from the renal pelvis into the duodenum and perinephric regions. Suprarenal and infrarenal PCD catheters and PCN catheter are seen in-situ. CT nephrostogram; f) shows injected contrast in the third part of duodenum.



[Table/Fig-2]: Contrast CT done after a month shows; a) small renal parenchymal air foci; and; b) minimal infrarenal fluid collection; c) Conventional Nephrostogram shows no evidence of pyeloduodenal fistula.

The patient is doing well at 12 months of follow up. Ultrasonography showed complete resolution of the collection. Serum creatinine was 1.1 mg/dL and Glomerular Filtration Rate (GFR) was 16 mL/min for right kidney and 45 mL/min for the left kidney.

DISCUSSION

Emphysematous Pyelonephritis (EPN) is a necrotizing infection of the renal parenchyma and surrounding areas that results in air containing collection in the renal parenchyma, collecting system or perinephric tissue [2]. More than 90% of cases occur in diabetics

with poor glycemic control. Other predisposing factors include urinary tract obstruction, polycystic kidneys, end-stage renal disease and immunosuppression. EPN is more common in women probably due to their increased susceptibility to urinary tract infections [3]. Extension of the infection to the retroperitoneum is common while involvement of the adjacent bowel is rare.

Most reno-alimentary fistulae occur due to perirenal spread of primary renal pathology. The most prevalent site is renocolic followed by renoduodenal [4]. Renoduodenal fistulae usually occur between the right renal pelvis and the second part of the duodenum because of the close proximity, absence of an intervening peritoneal layer and the relative immobility of the duodenum [5,6]. Pyeloduodenal fistulae may be spontaneous or traumatic [6,7]. Spontaneous pyeloduodenal fistulae are mostly due to chronic renal inflammatory disease such as chronic pyelonephritis and are more likely in the presence of urinary tract obstruction usually by calculi [5-7].

Tuberculosis was a frequent cause before effective chemotherapy [6]. Few cases due to squamous cell carcinoma, transitional cell carcinoma and adenocarcinoma of the renal pelvis have also been reported [8-10]. Primary diseases in the Gastrointestinal Tract (GI) such as gastric or duodenal ulceration, Crohn's disease, tuberculosis and pancreatitis are rare causes of pyeloduodenal fistula [4,6,11,12]. Iatrogenic causes are the most common aetiology of traumatic pyeloduodenal fistulae and include - percutaneous nephrolithotomy, PCN tube placement, ureteral catheterization, surgical error (drainage of a supposed pancreatic cyst into the renal pelvis), and gastrostomy tube placement [5,6].

The most common presenting complaints are flank pain, upper gastrointestinal symptoms, general malaise and weight loss, urinary frequency and urgency. The most common physical findings are fever, palpable flank mass and flank tenderness. Pyuria is seen in 80% patients and positive urine cultures in 83% cases [5,6].

Pyeloduodenal fistulae are difficult to diagnose. Antegrade pyelography is the method of choice for diagnosis and also allows subsequent drainage if required [6]. In our case the diagnosis was unsuspected and incidental. A PCN was done for a suspected urinary leak and post PCN antegrade pyelogram demonstrated the pyeloduodenal fistula along with perinephric urinary leak from the fistula site.

CT is the modality of choice for evaluating patients with EPN. Our case showed renal and perirenal gas containing fluid collections with spread beyond the Gerota's fascia as suggested by the involvement of the right psoas muscle and the occurrence of pyeloduodenal fistula and therefore fitted into Type 2 of the classification proposed by Wan YL et al., and Class 3B of Huang and Tseng's classification of EPN [3,13].

Treatment of pyeloduodenal fistula is tailored to the clinical situation and aetiology of the fistula [5]. The underlying cause must be treated as in cases of pyelonephritis [14]. If renal function is adequate, attempt should be made to conserve the kidney [7]. Initial non-surgical conservative therapy with antibiotics, bowel rest and relief of urinary obstruction by nephrostomy tubes or stents may be attempted and surgery reserved for recalcitrant fistulas [5,14,15]. Surgical management in patients with functioning kidneys includes removal of foreign bodies (if present) and excision of the fistula with primary repair of the urinary and GI tracts with re-establishment of unobstructed function of each system [5,14,16]. When renal function is poor, nephrectomy with duodenal repair should be considered [5,16].

CONCLUSION

CT guided percutaneous drainage along with PCN is an alternate to nephrectomy for the management of EPN if renal function is adequate.

REFERENCES

- [1] Huang JJ, Tseng CC. Emphysematous pyelonephritis: clinicoradiological classification, management, prognosis, and pathogenesis. *Arch Intern Med.* 2000;160(6):797-805.
- [2] Pontin AR, Barnes RD. Current management of emphysematous pyelonephritis. *Nat Rev Urol.* 2009;6(5):272-79.
- [3] Stofilas A, Manouras A, Lagoudianakis EE, Kotzadimitriou A, Pappas A, Chrysikos I, et al. Emphysematous pyelonephritis, a rare cause of pneumoperitoneum: a case report and review of literature. *Cases J.* 2008;1(1):91.
- [4] Newman B. Duodenorenal fistula. *Pediatr Radiol.* 2004;34(4):343-7.
- [5] Ginsberg DA, Stein JP, Grossfeld GD, Tarter T, Skinner DG. Traumatic pyeloduodenal fistula: A case report and review of the literature. *Urology.* 1996;47(4):588-91.
- [6] Desmond JM, Evans SE, Couch A, Morewood DJ. Pyeloduodenal fistulae. A report of two cases and review of the literature. *Clin Radiol.* 1989;40(3):267-70.
- [7] Evans PF. Spontaneous pyelo-jejunal fistula. *Postgrad Med J.* 1990;66(781):965-67.
- [8] Hernandez DJ, Schaeffer EM, Allaf ME. Pyeloduodenal fistula due to advanced upper tract malignancy. *Urology.* 2007;69(6):1206-07.
- [9] Chen CH, Cheng HL, Tong YC, Pan CC. Spontaneous pyeloduodenal fistula: an unusual presentation in advanced renal transitional cell carcinoma. *Urology.* 2002;60(2):345.
- [10] Tsuchiya T, Yoh M, Ito Y, Ban Y. Primary adenocarcinoma of the renal pelvis with a pyeloduodenal fistula: a case report. *Hinyokika Kiyo.* 2001;47(6):421-23.
- [11] Nayir A, Kadioglu A, Sirin A, Emre S, Oney V. A case of an enterorenal fistula and pyelonephritis with air in the renal pelvis. *Pediatr Radiol.* 1995;25(3):229-30.
- [12] Lang EK, Hanano A, Rudman E. Pyeloduodenal fistula diagnosed on parenchymal excretory phase computerized tomography. *J Urol.* 2010;184(1):334.
- [13] Wan YL, Lo SK, Bullard MJ, Chang PL, Lee TY. Predictors of outcome in emphysematous pyelonephritis. *J Urol.* 1998;159(2):369-73.
- [14] Atalla MA, Tajkarimi K, Vinh D, Guarnaccia SP. Pyeloduodenal fistula. *J Urol.* 2009;181(6):2733-34.
- [15] Mooreville M, Elkouss GC, Schuster A, Pearce AE, Rosen J. Spontaneous renocolic fistula secondary to calculus pyonephrosis. *Urology.* 1988;31(2):147-50.
- [16] Roberts BJ, Giblin JG, Tehan TJ, Lynch JH. Ureteroduodenal fistula. *Urology.* 1996;48(2):301-02.

PARTICULARS OF CONTRIBUTORS:

1. Senior Resident, Department of Urology, Sanjay Gandhi Postgraduate Institute of Medical Sciences, Lucknow, Uttar Pradesh, India.
2. Associate Professor, Department of Radiology, Sanjay Gandhi Postgraduate Institute of Medical Sciences, Lucknow, Uttar Pradesh, India.
3. Senior Resident, Department of Urology, Sanjay Gandhi Postgraduate Institute of Medical Sciences, Lucknow, Uttar Pradesh, India.
4. Senior Resident, Department of Radiology, Sanjay Gandhi Postgraduate Institute of Medical Sciences, Lucknow, Uttar Pradesh, India.
5. Additional Professor, Department of Radiology, Sanjay Gandhi Postgraduate Institute of Medical Sciences, Lucknow, Uttar Pradesh, India.

NAME, ADDRESS, E-MAIL ID OF THE CORRESPONDING AUTHOR:

Dr. Hiralal,
Additional Professor, Department of Radiology, Sanjay Gandhi Postgraduate Institute of Medical Sciences,
Lucknow-226014, Uttar Pradesh, India.
E-mail: hiralal2007@yahoo.co.in

FINANCIAL OR OTHER COMPETING INTERESTS: None.

Date of Submission: **Jun 18, 2017**
Date of Peer Review: **Sep 22, 2017**
Date of Acceptance: **Sep 25, 2017**
Date of Publishing: **Nov 01, 2017**